



## CASUISTIC PAPER

Piotr Przyczyna<sup>1,2(ABCGF)</sup>, Elżbieta Trojnar<sup>1(ABCGF)</sup>, Dorota Bartusik-Aebisher<sup>3(DFG)</sup>,  
David Aebisher<sup>4(DFG)</sup>

# Numerous gastrointestinal tumors

<sup>1</sup> Clinical Provincial Hospital No. 2, Rzeszów, Poland

<sup>2</sup> Department of Pathomorphology, Institute of Medical Sciences, Medical College of Rzeszow University, Rzeszow, Poland

<sup>3</sup> Department of Biochemistry and General Chemistry, Institute of Medical Sciences, Medical College of Rzeszow University, Rzeszow, Poland

<sup>4</sup> Department of Photomedicine and Physical Chemistry, Institute of Medical Sciences, Medical College of Rzeszow University, Rzeszow, Poland

## ABSTRACT

**Introduction.** Gastrointestinal stromal tumor (GIST) is most often locate in the region of the stomach and the proximal part of the small intestine.

**Aim.** The multiple histopathological examination is described.

**Description of the case.** Multiple GISTs are rare neoplasms that originate from the interstitial cells are described.

**Conclusion.** GIST can occur in any part of the gut, they are most common in the stomach and small intestine, and less frequent in the colorectum and esophagus. Although their pathogenesis and clinical manifestations are different, these tumor syndromes confer a high risk for developing multiple neoplasms.

**Keywords.** gastrointestinal stromal tumor, histopathological examination, multiple neoplasms, small intestine

## Introduction

Gastrointestinal stromal tumor (GIST) arises from CD34 positive Cajal cells.<sup>1</sup> Although they may occur along the entire length of the digestive tract, they most often locate in the region of the stomach and the proximal part of the small intestine.<sup>2</sup> Occurs at a frequency of 0.68 per 100,000.<sup>3</sup> The main method of treatment is surgery, however, after describing the KIT or PDGFRA mutation, imatinib-directed therapy has become pos-

sible.<sup>4</sup> In addition, many types of mesenchymal tumors may arise in the gastrointestinal tract. Their names refer to the cells they resemble or the tissues from which they originate. Neoplasms of nerve casings are schwannomas or schwannomas. Their location in the small intestine is extremely rare.<sup>5</sup> Pre-operative diagnosis of this cancer is difficult. In Japan, none of the reported cases were correctly diagnosed before surgery.<sup>6</sup> Benign neoplasms of smooth muscle are myomas. They

**Corresponding author:** Piotr Przyczyna, email: piotrprzyczyna@gmail.com

**Participation of co-authors:** A – Author of the concept and objectives of paper; B – collection of data; C – implementation of research; D – elaborate, analysis and interpretation of data; E – statistical analysis; F – preparation of a manuscript; G – working out the literature; H – obtaining funds

Received: 18.04.2020 | Accepted: 21.06.2020

Publication date: December 2020

constitute about 30-35% of benign small intestine tumors.<sup>7</sup> These tumors are made of spindle cells and require differentiation between themselves.<sup>8</sup>

### Aim

The study presents a female patient with the presence of a small intestine tumor and a stomach tumor. Histological analysis assist in establishing a correct diagnosis.

### Description of the case

A 75-year-old female patient without a history of chronic disease was admitted to the Gastroenterology Clinic due to changes in the abdominal CT scan suggesting the presence of a small intestine tumor and a stomach tumor. In the gastroscopy performed, the impression of the posterior gastric wall is described. In balloon-derived enteroscopy, the oral jejunum was visualized in the jejunum, approximately 40-50 cm after the pylorus (below the Treitz ligament), a prominent fragment of the intestinal wall with pronation. 20 x 30 mm. Specimens from the lesion and from the macroscopically normal part of the jejunum were collected. In the results obtained from the Department of Pathology, the correct intestinal membrane was described, with edema, congestion and dilated vessels. After the surgical consultation, the patient was qualified for surgical treatment in planned mode. A month later, the patient was admitted to the Surgery Clinic. After the preparation, it was operated. Peripherally, the tumor was found in the distal part of the stomach, jejunum and ileum. Three preparations were sent for histopathological examination:

- Fragment of the small intestine (3.5 cm) with frill for 2.5 cm. In the muscle membrane of the intestine, the gray cohesive node is 0,3 cm without communication with the mucous membrane or mesentery.
- Fragment of the small intestine (3.5 cm) with a tumor 4.5 x 4.5x2 cm. Macroscopically, a gray tumor, cohesive bound to the muscle membrane.

- A fragment of the stomach measured along the curvature of greater 10 cm, along a 9 cm curvature with a 2.5 x 2.5 x 2.5 cm tumor located on the posterior wall and the greater curvature. At a distance of 3cm from the cut border and 4.5cm from the proximal border, a gray solid tumor limited to the muscle membrane. Intra- and postoperative course uncomplicated. The patient was discharged home.

### Results

The majority of GISTs occur as sporadic solitary neoplasms resulting from somatic mutations. Currently, there are no criteria for the diagnosis of primary versus metastatic tumors in patients with multiple tumors. The prognosis of patients with multiple GISTs is similar to that of patients with solitary tumors.

The results (Figures 1-6) in histopathological examination was as follow:

- Neuroma from Schwann cells of the small intestine: IHC: S100 (+), Desima (-), SMA (-), CD34 (-), CD117 (-), Ki67 (+) about 1%
- Leiomyoma of the small intestine: IHC: SMA (+), CD (-), CD117 (-)
- Gastrointestinal stromal tumor (GIST) pT2NoMX, Mitosis index 2/50 dpw IHC: CD117 (+), CD34 (+), SMA (-)

### Discussion

GISTs belong to a group of cancers called soft-tissue sarcomas. Soft-tissue sarcomas develop in the tissues that support and connect the body. Widely used diagnostic endoscopy allows to reduce the extent of the procedure.<sup>9</sup> However, it should be remembered that there is still no consensus of experts on important issues regarding gastrointestinal tumors. An example is the presence of necrosis in GISTs, and its translation into prognosis in patients.<sup>10</sup> CT or CAT scan are uses x-rays to make detailed pictures of the inside of soft-tissue sarcomas your body. CT scans can often show the size, shape, and place

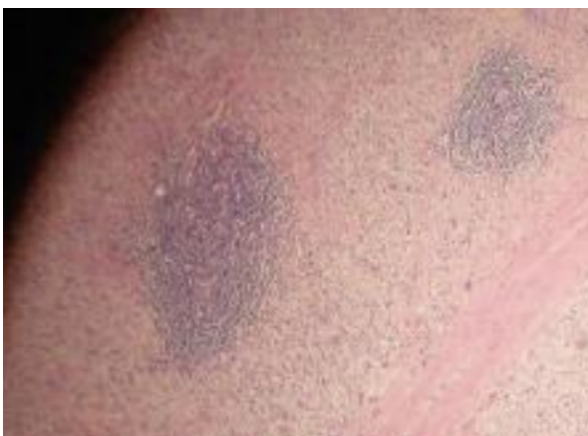

Fig. 1. Schwannoma HE 40x (Schwan4)

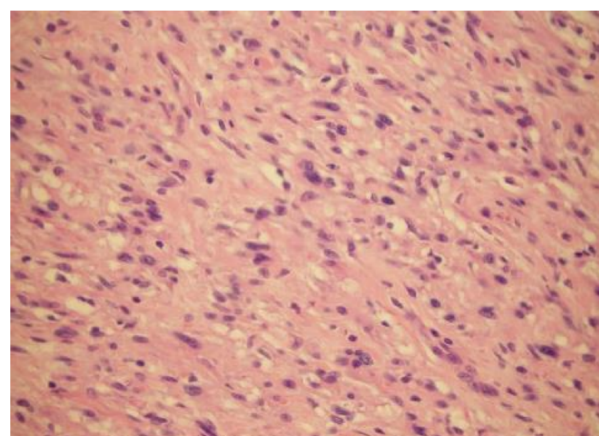


Fig. 2. Schwannoma HE 400x (Schwan40)

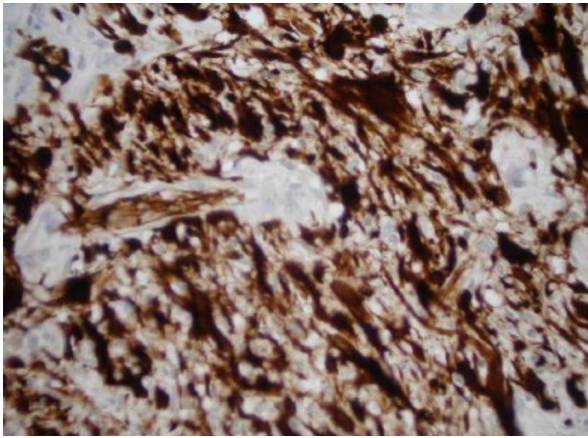


Fig. 3. Schwannoma S100 400x (SchwanS100)

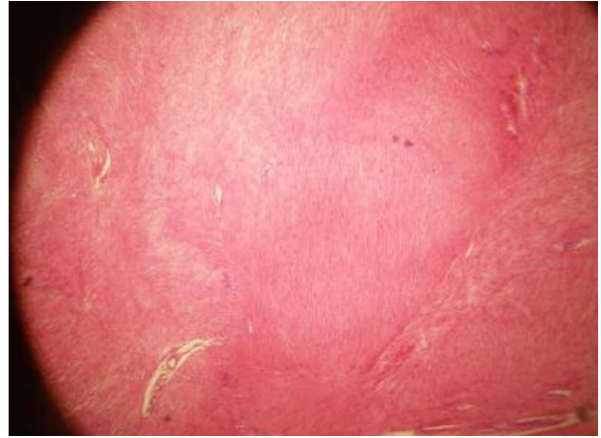


Fig. 4. Leiomyoma leiomyoma 40x (Myo4)

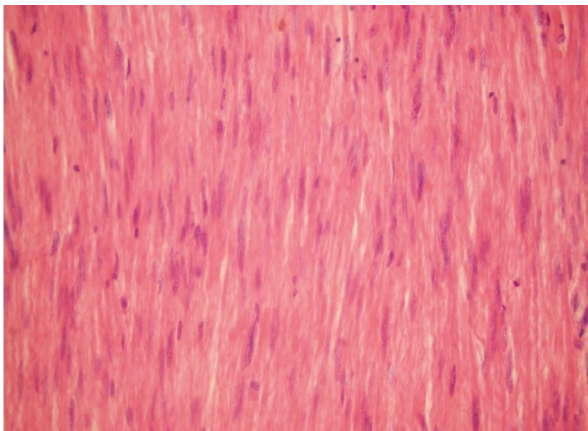


Fig. 5. Leiomyoma leiomyoma HE 400x (Myo40)

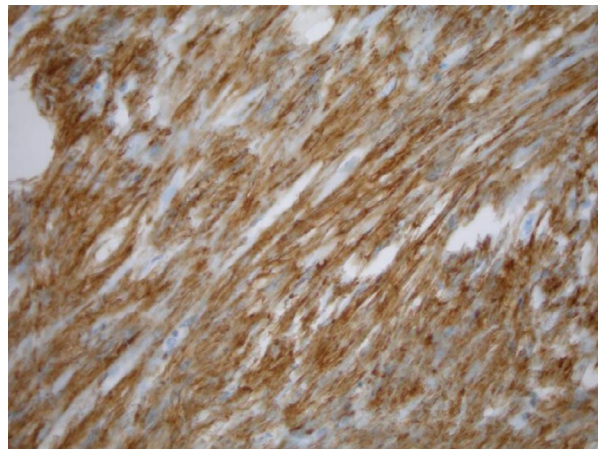


Fig. 6. Leiomyoma leiomyoma SMA 400x (MyoSMA)

of tumors in the GI tract. This test may also be done to see if cancer has spread.

## Conclusion

In clinical practice, if there are multiple tumors, we first think of a diffuse or inflammatory process. The described case reminds that one patient may have multiple, different tumors in one time.

## References

1. Fletcher CD, Berman JJ, Corless C, et al. Diagnosis of gastrointestinal stromal tumors: a consensus approach. *HumPathol.* 2002;33:459-465.
2. Miettinen M, Lasota J. Gastrointestinal stromal tumors—definition, clinical, histological, immunohistochemical, and molecular genetic features and differential diagnosis. *Virchows Arch.* 2001;438:1-12.
3. Ma GL, Murphy JD, Martinez ME, Sicklick JK. Epidemiology of gastrointestinal stromal tumors in the era of histology codes: results of a population-based study. *Cancer Epidemiol. Biomarkers Prev.* 2015;24:298-302
4. Sakin A, Can O, Arici S, Yasar N, Geredeli C, Demir C, Cihan S. Factors Affecting Disease-Free Survival in Operated Nonmetastatic Gastrointestinal Stromal Tumors. *J Surg Res.* 2019; 241:170-177.
5. Roulston G, Elwan H, Obeid N, Lirosi F. Ileal schwannoma causing intussusception in an adult. *BMJ Case Rep.* 2018;2018:bcr2018226247.
6. Nagai T, Fujiyoshi K, Takahashi K. Ileal schwannoma in which blood loss scintigraphy was useful for diagnosis. *Intern Med.* 2003;42:1178-1182.
7. Norton J, Barie PS, Bollinger RR, Chang AE, Lowry S, Mulvihill SJ, Pass HI, Thompson RW: *Surgery: Basic Science and Clinical Evidence (Norton: Surgery).* Springer, 2008. ISBN 978-0-387-30800-5.
8. Talley NJ. *Jelito cienkie, jelito grube, trzustka (Gastroenterologia i hepatologia w praktyce klinicznej).* Elsevier Urban & Partner, 2013. ISBN 978-83-7609-788-6.
9. Piazza L, Ferrara F, Pulvirenti A. Laparoscopic sleeve gastrectomy for bleeding GIST: clinical case. *Suppl Tumori.* 2005;4(3):S106-S107.
10. Yi M, Xia L, Zhou Y, Wu X, Zhuang W, Chen Y, Zhao R, Wan Q, Du L, Zhou Y. Prognostic value of tumor necrosis in gastrointestinal stromal tumor: A meta-analysis. *Medicine (Baltimore).* 2019;98(17):e15338.