



ORIGINAL PAPER

Mahmoud M. Gharaibeh ^{1(ABCDG)}, Ahmed Al Wadiya ^{2(DF)}, Ahmad Gharaibeh ^{3(CDEF)}

Cervical lymphadenitis as a result of (Hijab) pin prick in north of Jordan

¹ Teaching Department of Dentistry, Princes Basma Teaching Hospital, Irbid, Jordan

² Royal Derby Hospital, UK

³ Teaching Department of Orthopaedics and Musculoskeletal Trauma, Louis Pasteur University Hospital, LF UPJS Kosice, Slovakia

ABSTRACT

Introduction. Cervical lymph nodes are lymph nodes found in the neck. Hijab is a head cover worn by some Muslim women in the presence of any adult male outside of their immediate family, which usually covers the head, neck and chest. It is strictly forbidden to Muslim woman to unveil any single hair of her head, so they use many pins around the head to fix their Hijab. Often, while using pins they are self-pricked.

Aim. The main aim of our work is to reveal a new cause of lymphadenopathy, which is not known till now.

Material and methods. Retrospective study during the past five years among seventy-five female outpatients, visited our Oral and Maxillofacial clinic in dental department. Our data was collected according to medical history of patients; all female patients with cervical lymphadenopathy were using (A hijab).

Results. Data collected of 75 female patients. Lymphadenopathy causes were various. Most of these causes resulted from non-specific lymphadenitis (67 patients), 4 tuberculosis, 2 lymphoma, 2 cat scratch disease. Aetiology of 67 nonspecific lymphadenitis was 40 patients of dental cause, 10 of sore throat, 7 of acne vulgaris, 3 of mild facial injuries, and 7 of (Hijab pin pricks).

Conclusion. Hijab pin prick cervical lymphadenitis in Islamic communities is not uncommon and, unexplained cervical lymphadenitis should be considered as potential cause.

Keywords. Hijab, lymphadenitis, tuberculosis

Introduction

Cervical lymph nodes are lymph nodes found in the neck. There is 800 lymph nodes in the human body, 300 of them are in the neck.¹ Cervical lymph nodes are subject to a number of different pathological conditions including tumours, infections and inflammations.²

The American Academy of Otolaryngology system (2002) divides the cervical nodes into six levels numbered by Roman numerals I, II, Etc.³

Lymphadenitis is enlargement in one or more lymph nodes, usually due to infection. Lymph nodes are filled with white blood cells that help the body fight infec-

Corresponding author: Ahmad Gharaibeh, e-mail: gharaibeh@seznam.cz

Participation of co-authors: A – Author of the concept and objectives of paper; B – collection of data; C – implementation of research; D – elaborate, analysis and interpretation of data; E – statistical analysis; F – preparation of a manuscript; G – working out the literature; H – obtaining funds

Received: 15.07.2020 | Accepted: 13.10.2020

Publication date: December 2020

tions. When lymph nodes become infected, it is an indication that an infection started somewhere else in the body. Rarely, lymph nodes can enlarge due to cancer.⁴ Lymphadenitis may occur after skin infections or other infections caused by bacteria such as streptococcus or staphylococcus. Sometimes, it results from rare infections such as tuberculosis or cat scratch disease (bacterium *Bartonella henselae*).⁵

Hijab is a veil worn by some Muslim women in the presence of any male outside of their immediate family, which usually covers the head, neck and chest.⁶

It is strictly forbidden to Muslim woman to unveil any single hair of her head, so they use many pins around the head to fix their Hijab. Often, while using pins they are self-pricked. These pins as we know are not sterile or even clean and may cause local infection in the scalp and face, therefore, women start seeking help in our clinic with painful lymphadenitis usually in submental and submandibular region. Most of the patients are cancer phobic and some are as young as 10 years old!

Therapy of cervical lymphadenitis is achieved according to ethology, for nonspecific types we use antibiotic therapy and many times we allow the body to fight infection. For suppurative cases incision and drainage is needed. Surgical excision of the lymph node is often not needed, but only for persistent nodes over one year and for aesthetic reasons, since enlarged inflammatory lymph nodes can persist for many days, weeks, months and even years.⁷

Aim

The main aim of our work is to reveal a new cause of lymphadenopathy, which is not known till now.

Material and methods

Retrospective study, during the past five years from 1.1.2014 to 31.12.2018, seventy-five female out patients visited Oral and Maxillofacial clinic in the dental department of the Princess Basma Teaching Hospital and Al-Yarmuk Teaching Hospital (Irbid city, north of the Hashemite kingdom of Jordan). The annual average number of patients is 1837. Our data was collected according to medical history of the patients. Fine Needle Aspirations (FNA) cytology (Ziehl Neelsen stain), culture and polymerase chain reaction (PCR) were performed to confirm diagnosis. All female patients were using Hijab. Data analysis of the results was processed using the statistical functions of Microsoft Excel.

Results

Data collected of 75 female patients. Lymphadenopathy causes were various. Most of them resulted from nonspecific lymphadenitis 67 patients, 4 patients had tuberculosis diagnosed by histopathology test by detecting chronic granulomatous cells and to be followed by tu-

berculin skin test, 2 patients had lymphoma, 2 patients had cat scratch disease (Table 1).

Table 1. Aetiology of all cases of lymphadenopathy

	Diagnosis	Number	Percentage
1	Nonspecific lymphadenitis	67	89.33%
2	Tuberculosis	4	5.33%
3	Lymphoma	2	2.66%
4	Cat scratch disease	2	2.66%
	Total	75	100%

The mean was 24.13, standard error 16.09, median 18.75, standard deviation 32.18, sample variance 1035.58, range 65, minimum 2, maximum 67, sum 75, count 75, kurtosis 17.48 and skewness 17.99. 67 nonspecific lymphadenitis patients have age categories as in table 2.

Table 2. Age categories of lymphadenitis

Age (years)	Number of patients	Percentage
10-20	35	52.23%
20-30	15	22.38%
30-40	10	14.92%
40-50	4	5.97%
50-60	2	2.98%
over 60	1	1.49%
Total	67	100%

Aetiology of 67 patients was nonspecific lymphadenitis, 40 patients of dental cause, 10 of sore throat, 7 of acne vulgaris, 3 of mild facial injuries, and 7 of (Hijab pin pricks) - Figure 1.

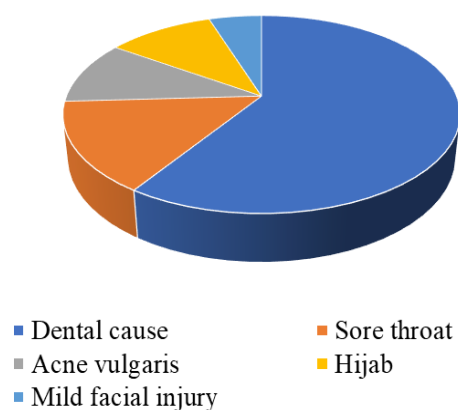


Fig. 1. Ethology of nonspecific lymphadenitis

The mean was 11.17, standard error 5.24, median 7, standard deviation 12.82, sample variance 164.57, range 34, minimum 1, maximum 35, count 67, kurtosis 8.87 and skewness 1.62

Hijab pin-prick patients' total number was 7, most of them were among young age (Table 3).

Table 3. Age categories of hijab patients

Age group by years	Number	Percentage
10y – 20y	4	57.14%
20y – 30y	2	28.57%
over 30y	1	14.29%
total	7	100.00%

It has been noticed low incidence in older ages as shown in table 3.

Therapy of lymphadenopathy was according to aetiology. We treated Hijab pin prick infections with cervical lymphadenitis by cephalosporins of first generation orally, as we treat skin infections, which is most common caused by *Staphylococcus aureus*. All cases cured and lymph nodes enlargement disappeared after few days, however, they can last up to several weeks.

Discussion

This study is the first of its kind, in which lymphadenitis has been associated with hijab pin pricks. Therefore, it is encouraged to continue this research to further obtain insight into this field.

Lymphadenitis has high prevalence in children.⁸ The immune system is strong in the first three decades of life. When a juvenile female uses Hijab, it means that she is not well experienced to fix it, that leads to self-pricking more than older women, further juvenile is more sensitive to head and face infections.⁸

Pins used for Hijab purpose are not sterile or even clean. So self-pricking leads often to infection of the inner layers of skin (cellulitis), the bacteria most commonly involved are *Streptococcus ssp.* and *S. aureus*. Physicians must treat it as serious skin infection by antibiotics and to use mild analgesics to relief tenderness of the reactive lymph node in the neck. In children sometimes reactive lymph nodes become suppurative and need incision and drainage.⁹

We used first-generation cephalosporin, because is currently recommended for cellulitis without abscess.¹⁰

It is highly recommended for physicians working in Islamic countries or Islamic communities in non-Islamic countries to consider the medical challenge. When physician faces unexplained cervical lymphadenitis in female head veiled patient, he should think about self-pricking of Hijab pins.

The biggest problem was to persuade the patients that this painful enlargement of the mass is not a cancer and, when they were told that we must take a biopsy they became more anxious and cancer phobic. Phobia was dismissed when we read the pathological report for

FNA (Fine Needle Aspiration), which took two to three weeks to be finalised. It was at this point that we were able to convince the patient that the biopsy was not cancerous.¹¹

Conclusion

Hijab pin prick cervical lymphadenitis in Islamic communities is not uncommon and, unexplained cervical lymphadenitis should be considered as potential cause. Treatment of choice is first generation of cephalosporins and if lymph node becomes suppurative, incision and drainage should be performed but it is rare in such conditions.

In the media we recommend awareness campaigns to avoid this phenomenon and cancer phobia of affected females.

References

- Mukherji SK, Gujar S, Londy FJ. A Simplified Approach to the Lymph Nodes of the Neck. *Neurographics*. 2002.
- Eisenmenger LB, Wiggins RH. Imaging of head and neck lymph nodes. *Radiol Clin North Am*. 2015;53(1):115–132.
- Robbins KT, Garry C, Levine PA, et al. Neck Dissection Classification Update. *Arch Otolaryngol Head Neck Surg*. 2002;128(7):747–856.
- Balm AJM, van Velthuysen MLE, Hoebbers FJP, Vogel WV, van den Brekel MWM. Diagnosis and Treatment of a Neck Node Swelling Suspicious for a Malignancy: An Algorithmic Approach. *Int J Surg Oncol*. 2010; 2010:581540.
- Lindeboom JA, Prins JM, Bruijnesteijn van Coppenraet ES, Lindeboom R, Kuijper EJ. Cervicofacial lymphadenitis in children caused by *Mycobacterium haemophilum*. *Clin Infect Dis*. 2005;41(11):1569–1575.
- El Guindi F, Zahur S. “Hijab”. The Oxford Encyclopedia of the Islamic World. Oxford University Press 2016.
- Lindeboom JA. Conservative wait-and-see therapy versus antibiotic treatment for nontuberculous mycobacterial cervicofacial lymphadenitis in children. *Clin Infect Dis*. 2011;52(2):180–184.
- Sachin D, Trusha R. Cervical Lymphadenopathy in Children-A Clinical Approach. *IJCMR*. 2016;3(4):1207–1210.
- Vary JC, O'Connor KM. Common Dermatologic Conditions. *Med Clin North Am*. 2014;98(3):445–485.
- Stevens DL, Bisno AL, Chambers HF, et al. Practice guidelines for the diagnosis and management of skin and soft tissue infections: 2014 update by the Infectious Diseases Society of America. *Clin Infect Dis*. 2014;59(2):e10–52.
- Sah SK, Pant R, Piper K, Chowdhury TA, Crean SJ. Recurrent Kikuchi–Fujimoto disease: Case report. *Br J Oral Maxillofac Surg*. 2007;45(3):231–233.