







## CASUISTIC PAPER

Fatma Hüsniye Dilek <sup>1(ABDF)</sup>, Furkan Tosun <sup>2(CG)</sup>, Arif Atay <sup>2(DG)</sup>,  
Osman Nuri Dilek <sup>2(AFG)</sup>

# Pancreatic tumor metastasis to the navel in a case with three primary tumors – case report and review of the literature

<sup>1</sup> Department of Pathology, School of Medicine, İzmir Katip Celebi University, İzmir, Turkey

<sup>2</sup> Department of Surgery, School of Medicine, İzmir Katip Celebi University, İzmir, Turkey

## ABSTRACT

**Introduction.** Sister Mary Joseph nodule (SMJN) is a metastasis that can occur in the umbilical region due to many tumors in the abdomen. Most of the cases are of gastrointestinal system origin and are often an indicator of poor prognosis. It can be seen in 1-3% of intraabdominal and pelvic malignancies. In the literature, around 300 studies are presented, mostly in the form of case reports. Very few (7-9%) of the cases with SMJN are from pancreatic origin. In our literature review, we found that in the majority (>90%) of SMJN cases due to pancreatic tumors, the lesions originated from the pancreatic tail and/or body, and tumor marker Ca-19.9 was very high in most cases (>90%).

**Aim.** Here, the case of SMJN seen in a patient with three different primary tumors was discussed in the light of the literature data.

**Description of the case.** Here, our case, whose third primary malignancy was detected in the pancreas in the PET/CT examination performed to investigate the origin of SMJN in a 68-year-old female patient who had undergone surgery due to breast in 2011 and endometrium cancers in 2018 and came with umbilical metastasis, is presented in the light of the literature data.

**Conclusion.** As a result, in our case, which was followed up due to two primary tumors, it became important to know the origin of the SMJN that occurred due to the third primary tumor detected during the CT and PET/CT examination due to the newly emerging SMJN. It is important to know the origin and histopathological features of the SMJN in order to determine the treatment to the patient.

**Keywords.** breast, endometrium, multiple primary tumor, pancreas, Sister Mary Joseph's nodule, umbilical mass

## Introduction

Sister Mary Joseph nodule (SMJN) is a metastasis that can occur in the umbilical region due to many tumors in the abdomen. The tumor is thought to metastasize to the umbilical region through lymphatic ducts, blood vessels, neighborhood and embryonic residues (1). The majority of cases (75-90%) are adenocarcinoma. It con-

stitutes 30-60% of malignant tumors located in the umbilical region. It can be seen in 1-3% of intraabdominal and pelvic malignancies. Although most of the cases originated from the gastrointestinal tract, cases of biliary tract, endometrium, ovary, lung, bladder and appendix have also been reported.<sup>1-5</sup> Although the average survival time of patients with SMJN is 11 months, this

**Corresponding author:** Osman Nuri Dilek, e-mail: [osmannuridilek@gmail.com](mailto:osmannuridilek@gmail.com)

**Participation of co-authors:** A – Author of the concept and objectives of paper; B – collection of data; C – implementation of research; D – elaborate, analysis and interpretation of data; E – statistical analysis; F – preparation of a manuscript; G – working out the literature; H – obtaining funds

Received: 25.06.2020 | Accepted: 29.07.2020

Publication date: September 2020

period may exceed 2 years in patients who have the chance of chemotherapy and surgical treatment (<15%). In the literature, around 300 studies (about 450 cases) are presented, mostly in the form of case reports.<sup>1,2</sup>

### Aim

Here, the case of SMJN seen in a patient with three different primary tumors was discussed in the light of the literature data.

### Description of the case

A 68-year-old female patient underwent modified radical mastectomy in 2011 due to invasive ductal carcinoma. Hysterectomy was applied in 2018 due to endometrioid type endometrium cancer. During her periodic follow-up, the patient applied to her physician a month ago with complaints of swelling and discharge in the navel (Figure 1).

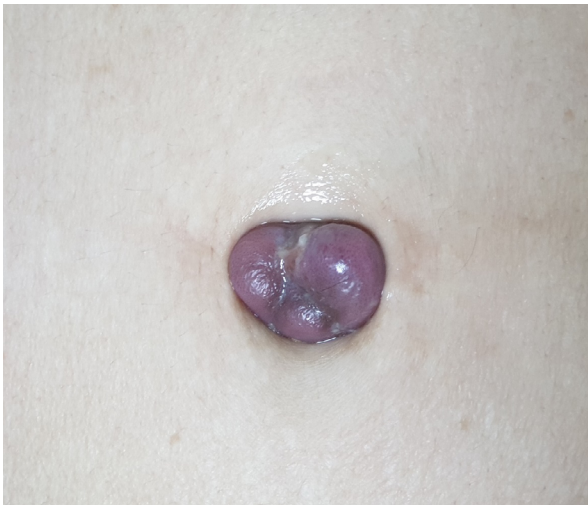

Fig. 1. Sister Mary Joseph nodule in the navel

As a result of abdominal CT performed to the patient referred to our clinic, a malignant mass in the pancreatic tail and a lesion showing involvement in the navel were identified (Figure 2).

No genetic predisposition was detected in his family's questioning. The presence of hypermetabolic involvement in both lesions was demonstrated by PET/CT (Figure 3).

Radiological findings related to local recurrence of breast and endometrium tumors were not found. Serum Ca 19.9 value of our patient was found to be very high (65.951 U/mL). As a result of histopathological examination of the incisional biopsy specimen made from the mass in the navel; Malignant tumoral tissue forming glandular structures was seen under the skin. Tumor cells had hyperchromatic nuclei, large eosinophilic cytoplasm, some with secretions. It was thought to be compatible with a pancreatobiliary type adenocarcinoma morphologically. As a result of the immunohistochemical study; Diffuse positive staining was detected with cytokeratin 7, cytokeratin 19 and GATA3, while negative staining was detected with cytokeratin 20, estrogen receptor, progesterone receptor, mammoglobin, GFCD, WT1 and CDX2 (Figure 4).

Contrary to expectations, the lesion was not due to breast or endometrium, but to pancreatic origin. The patient has been receiving chemotherapy protocols for 3 months. As a routine procedure, Written-signed informed consent form was obtained from the patient for treatment modalities and publication.

### Discussion

Sister Mary Joseph's nodule is a phenomenon accepted by surgeons as an indicator of poor prognosis.<sup>1</sup> The diagnosis of SMJN can usually be made easily by physi-

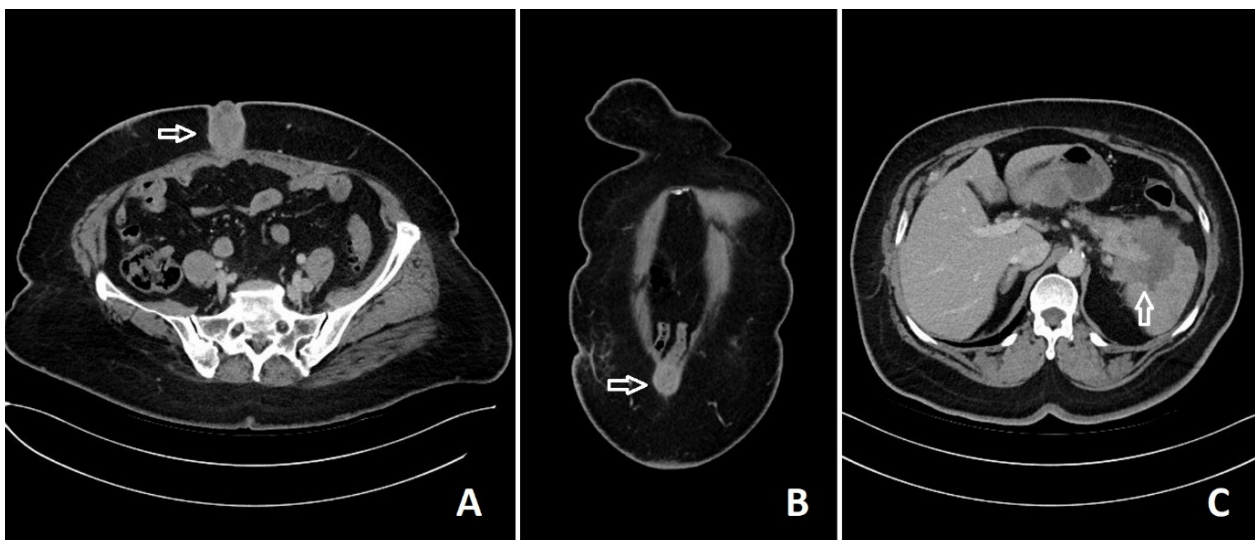
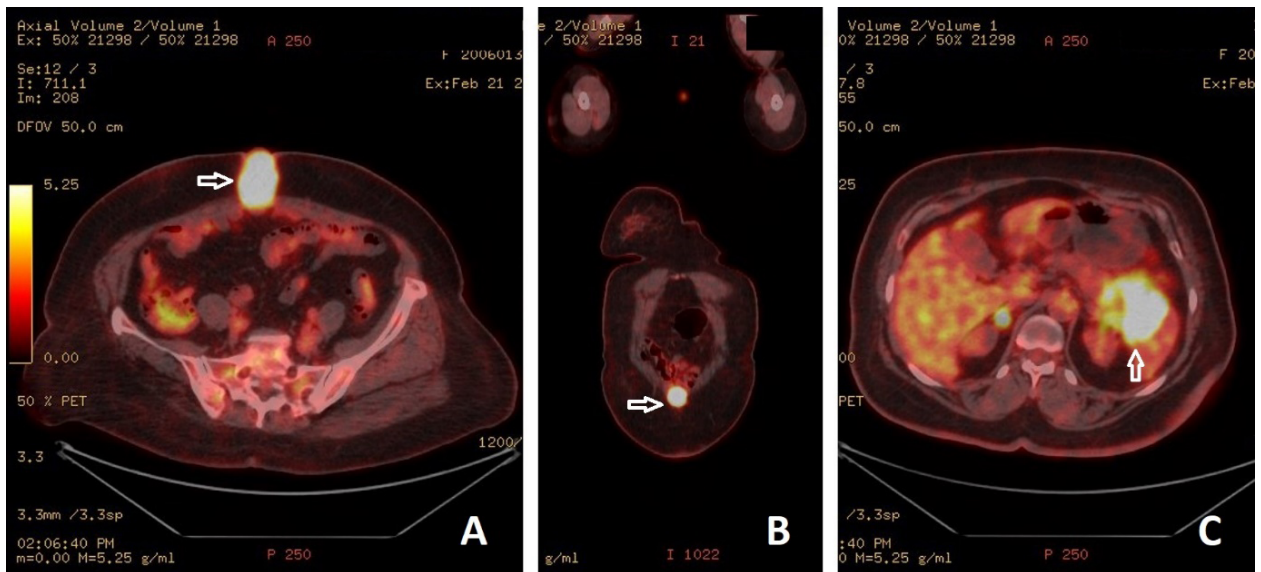
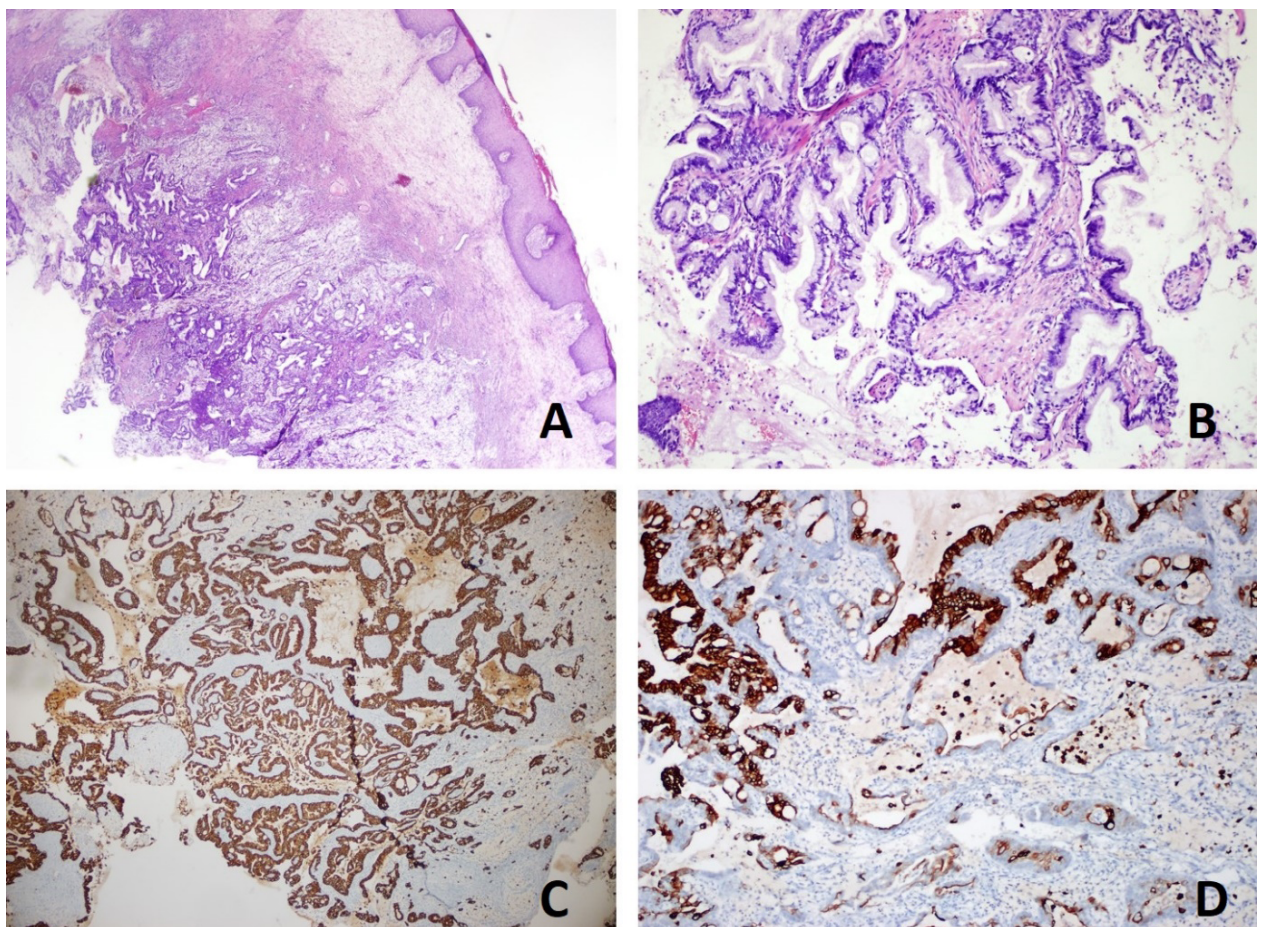


Fig. 2. The abdominal CT axial (A) and coronal (B) sections show the appearance of SMJN, and the axial section (C) shows the tumoral lesion (Arrows) in the tail of the pancreas



**Fig. 3.** PET/CT axial (A) and coronal (B) sections show the appearance of SMJN, and the axial section (C) shows the tumoral lesion (Arrows) in the tail of the pancreas



**Fig. 4.** These pictures show the presence of adenocarcinoma (A) under the skin tissue (HE x 20). Some of the irregular adenoid structures (B) contain mucin-making cells (100x) (H&E stain). Adenocarcinoma shows diffuse cytokeratin 19 (C) positivity (CK-19 x 40), and patch-style cytokeratin (D) positivity (100x) (CK-20)

cal examination. Mass-forming lesions can be revealed by radiological examinations.<sup>6</sup> The diagnosis of SMJN can usually be made easily by physical examination.

Mass-forming lesions can be revealed by radiological examinations. While more than half of the cases with SMJN (52-55%) originate from digestiv system organs

and 28-30% from reproductive system organs, primary focus may not be found in 15-20% of the cases.<sup>2,7</sup> 7-9% of SMJN cases reported in the literature are of pancreatic origin.<sup>1,2,4</sup> We did not encounter three primary tumor cases and SMJN cases with pancreatic tumor.<sup>8,9</sup> We think that our case is the first case in the literature with these features.<sup>3,4</sup> Microscopic examination of our case showed that tumor had simple, large glands are lined by a single layer of cells with round nuclei. Some glands have abundant mucinous cytoplasm and are remarkably well formed. This pattern resembles carcinomas of the pancreas and bile ducts not endometrial or breast carcinoma. Commonly used breast markers such as mam-maglobin, gross cystic disease fluid protein, ER,PR were negative. There is a high rate of expression in breast carcinoma of GATA3, and ER, PR in endometrial cancers. Our case was not showed expression for ER,PR. Also, CK7 and CK19 expressed relatively diffusely and strongly in the vast majority of pancreatobiliary-type ampullary adenocarcinoma, and diagnosis was diagnosis was determined in compatible with pancreatobiliary type adenocarcinoma metastasis.

In our literature review, we found that the majority (>90%) of lesions defined as pancreatic SMJN were lesions originating from the tail of the pancreas and less than the body of the pancreas (2,3,5). In 4 cases of pancreatic tumors and SMJN series of Ozaki et al., All of the cases were defined as pancreatic body and tail origin.<sup>3</sup> It was noteworthy that most of the patients (>90%) with pancreatic tumors with SMJN whose blood tumor markers were examined had a high level of Ca 19-9.<sup>1-3,9,10</sup> It was also found to be very high in our patient. Most of the patients with SMJN (>90%) diagnosed in the literature also had liver metastases. Our patient also had metastases in the liver.

## Conclusion

As a result, in our case, which was followed up due to two primary tumors, it became important to know the origin of the SMJN that occurred due to the third primary tumor detected during the CT and PET/CT examination due to the newly emerging SMJN. It is important

to know the origin and histopathological features of the SMJN in order to determine the treatment to the patient.

## References

1. Piura B. Umbilical metastasis: Sister Mary Joseph's nodule. *Harefuah*. 2006;145(7):505-509.
2. Yendluri V, Centeno B, Springett GM. Pancreatic cancer presenting as a Sister Mary Joseph's nodule: case report and update of the literature. *Pancreas*. 2007;34(1):161-164.
3. Ozaki N, Takamori H, Baba H. Sister Mary Joseph's nodule derived from pancreatic cancer. *J Hepatobiliary Pancreat Sci*. 2011;18(1):119-121.
4. Dilek ON, Ozsay O, Karaisli S, Ö Gür E, Er A, G Hacıyanli S, Kar H, H Dilek F. Striking Multiple Primary Tumors that underwent Whipple Procedure due to Periampullary Carcinoma: An Analysis of 21 Cases *Euroasian J Hepato-gastroenterol*. 2018;8(1):1-5.
5. Marcacuzco Quinto AA, Nutu OA, Justo Alonso I. Umbilical metastasis of a pancreatic origin: Sister Mary Joseph's nodule. *Rev Esp Enferm Dig*. 2019;111(12):977-978.
6. Gattu R, Sakla N, Singh G, Sadler M. Sister Mary Joseph nodule: an often overlooked or misdiagnosed entity on imaging. *Clin Imaging*. 2019;60(2):177-179.
7. De Angeli M, Carosi M, Vizza E, Corrado G. Sister Mary Joseph's nodule in endometrial cancer: A case report and review of the literature. *J Cancer Res Ther*. 2019;15(6):1408-1410.
8. Whitworth J, Smith PS, Martin JE, et al. Comprehensive cancer-predisposition gene testing in an adult multiple primary tumor series shows a broad range of deleterious variants and atypical tumor phenotypes. *Am J Hum Genet*. 2018;103(1):3-18.
9. Limmathurotsakul D, Rernimitr P, Korkij W, Noppakun N, Kullavanijaya P, Rerknimitr R. Metastatic mucinous cystic adenocarcinoma of the pancreas presenting as Sister Mary Joseph's nodule. *JOP*. 2007;8:344-349.
10. Premkumar M, Rangegowda D, Vyas T, Grover S, Joshi YK, Sharma C, Sahney A. Cholangiocarcinoma presenting as a Sister Mary Joseph Nodule. *ACG Case Rep J*. 2016;3(3):209-211.