





## CASUISTIC PAPER

Katarzyna Błochowiak <sup>1</sup>(ADFG), Bartłomiej Kamiński <sup>2</sup>(BCD)

# Combined aplasia of frontal and sphenoid sinuses with hypoplasia of the maxillary sinus

<sup>1</sup> Department of Oral Surgery and Periodontology, Poznan University of Medical Sciences, Poznań, Poland

<sup>2</sup> Otolaryngology Ward, District Hospital in Skarżysko-Kamienna, Skarżysko-Kamienna, Poland

### ABSTRACT

**Introduction.** Combined aplasia of multiple sinuses is extremely rare. Agenesis of the paranasal sinuses is an uncommon clinical condition that appears mainly in the frontal (12%) and maxillary (5-6%) sinuses.

**Case report.** In this paper, we present the case of a 74-year-old woman with combined frontal and sphenoid sinus aplasia accompanied by unilateral maxillary sinus hypoplasia. The findings were confirmed by a computed tomography scan of paranasal sinuses. The reason for admission was persistent headache, numbness of the left cheek and left alveolar process, and occasional nasal blockage.

**Discussion.** The uniqueness of our case is that the patient is an elderly female with combined aplasia of the frontal and sphenoid sinus with hypoplastic maxillary sinuses, whereas previously reported cases were found in children and in young adults.

**Summary and conclusions.** These anomalies can be misdiagnosed as chronic sinusitis or neoplasm. All potential sinus anomalies will have clinical implications and will hinder conventional and functional endoscopic sinus surgery.

**Keywords.** frontal sinus aplasia, maxillary sinus hypoplasia, paranasal sinus anomalies, paranasal sinus aplasia,

### Introduction

The paranasal sinuses are air-filled spaces located within the bones of the face and skull. They are thought to contribute to voice resonance, humidifying and warming inhaled air, increasing olfactory membrane area, absorbing shock to the face and head, providing thermal insulation for the brain, contributing to facial growth, representing vestigial structures, and to lighten the skull and facial bones.<sup>1,2</sup> The process through which the paranasal sinuses develop begins prenatally. They vary in terms of the development period and the level of pneu-

matisation. They can manifest different anomalies, for instance proper sinus development can be disturbed by many harmful factors and is associated with pneumatization. Fractures, tumors, mucocoeles, primary ciliary dyskinesia, infections, and some syndromes may have adverse effects on paranasal sinus development.<sup>2,3</sup> Various other clinical syndromes are found to be associated with agenesis of paranasal sinuses, such as Down's syndrome, cystic fibrosis, craniosynostosis and osteodysplasia.<sup>2</sup> Combined aplasia of multiple sinuses is extremely rare, as is hypoplasia of other sinuses. Agenesis

**Corresponding author:** Katarzyna Błochowiak, e-mail: [kasia@naszdentysta.com.pl](mailto:kasia@naszdentysta.com.pl)

**Participation of co-authors:** A – Author of the concept and objectives of paper; B – collection of data; C – implementation of research; D – elaborate, analysis and interpretation of data; E – statistical analysis; F – preparation of a manuscript; G – working out the literature; H – obtaining funds

Received: 17.05.2018 | Accepted: 02.06.2018

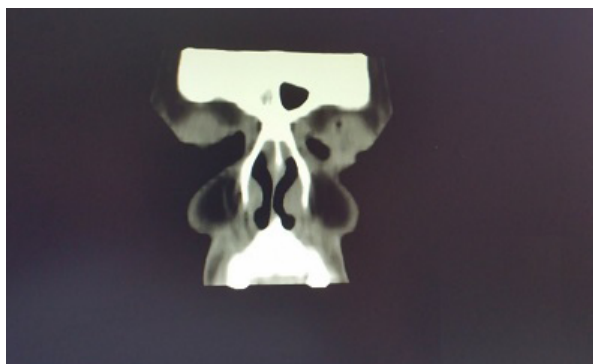Publication date: June 2018

of the paranasal sinuses is an uncommon clinical condition that appears mainly in the frontal (12%) and maxillary (5-6%) sinuses.<sup>2</sup> These anomalies can be asymptomatic or misdiagnosed as chronic sinusitis or neoplasm. All potential sinus anomalies will have clinical implications and will hinder conventional and functional endoscopic sinus surgery.<sup>4</sup>

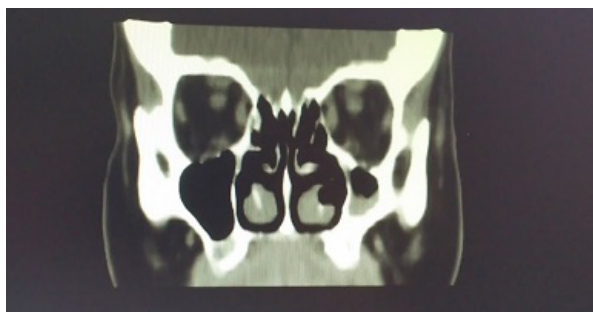In this paper, we present the case of a 74-year-old woman with combined frontal and sphenoid sinus aplasia accompanied by unilateral maxillary sinus hypoplasia. The findings were confirmed on a non-contrast computed tomography scan of paranasal sinuses.

### Case report

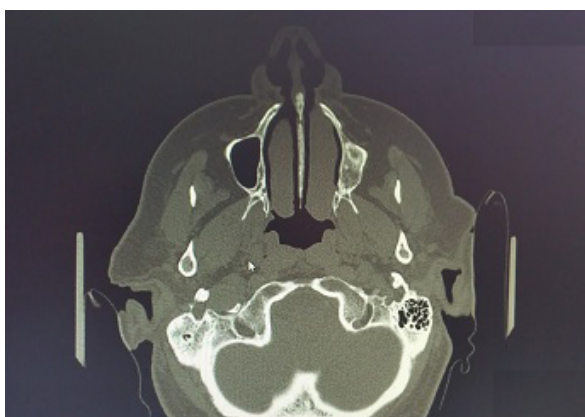A 74-year-old woman was admitted to the Department of Laryngology of the District Hospital in Skarżysko-Kamienna. The reason for admission was persistent headache, numbness of the left cheek and left alveolar process, and occasional nasal blockage. Her complaints persisted throughout the day, and were aggravated in the early morning and during cold weather. She had already undergone medical treatment on several previous occasions, but with only temporary relief. There was no family history of similar complaints. No past history of any nasal surgery, facial trauma or any systemic disease involving the skeletal system was found, and haematological and other laboratory findings were normal. She was referred to a dentist to exclude all possible dental and oral abnormalities. A dental examination at the Department of Oral Surgery Poznan University of Medi-



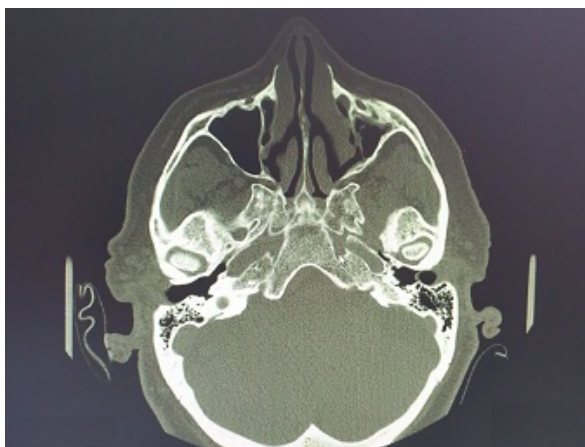
**Fig. 1.** Aplasia of the right frontal sinus



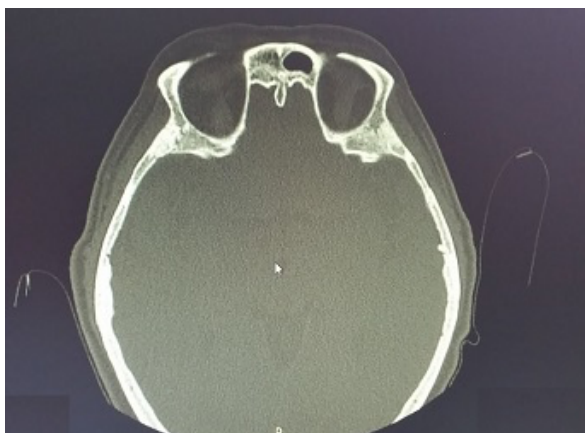**Fig. 2.** Hypoplasia of the left maxillary sinus



**Fig. 3.** Hypoplasia of the left maxillary sinus, sclerotic structure of the mastoid process of the right temporal bone



**Fig. 4.** Aplasia of the right sphenoid sinus and the hypoplasia of the left maxillary sinus



**Fig. 5.** Aplasia of the right frontal sinus

cal Sciences revealed no dental and oral abnormalities and diseases. The ENR examination revealed no other clinical abnormalities. Computed tomography (CT) detected unilateral aplasia of the right frontal and right sphenoid sinuses accompanied by unilateral hyperplasia of the left maxillary sinus (Fig. 1, Fig. 2, Fig. 3).

Additionally, CT revealed the sclerotic structure of the mastoid process of the right temporal bone and the

thickness of the inner lamina of the frontal bone, sphenoid and parietal bones (Fig. 4, Fig. 5).

## Discussion

Isolated sinus aplasia or hypoplasia is detected quite often and can result from congenital or acquired post-traumatic or post-infectious abnormalities. However, combined or bilateral sinus aplasia or hypoplasia are extremely rare. Agenesis of the frontal sinus is the most common and accounts for 12% of cases. In some populations, it appears at a higher proportion. Furthermore, the configuration and development of frontal sinus and its possible anomalies within each population also depends upon the constitutional (age, gender, hormones and craniofacial configuration) and environmental factors (climatic conditions and local inflammation).<sup>5,6</sup> A bilateral absence and unilateral absence of the frontal sinuses was found in 3.8% and 4.8% of cases, respectively.<sup>7</sup> According to Ozcan et al., combined aplasia of both frontal and maxillary sinuses is the most common radiological and clinical pattern and can have clinical implications for sinus surgery.<sup>8</sup> The findings of aplasia/hypoplasia of the frontal and or sphenoidal sinuses may be part of the spectrum of primary ciliary dyskinesia and this finding should prompt exclusion of this condition.<sup>9</sup> The uniqueness of our case is that the patient is an elderly female with combined aplasia of the frontal and sphenoid sinus with hypoplastic maxillary sinuses, whereas previously reported cases were found in children and in young adults. The sinus anomalies were asymptomatic for many years and were not properly diagnosed. Frontal sinus aplasia is found more often in young women than men.<sup>10</sup> It is not known whether there is a female predilection for frontal and sphenoid sinus aplasia. The frontal sinus is absent at birth and develops after the age of 2 years. The frontal sinuses arise from one of several outgrowths that originate in the region of the frontal recess of the nose, and their site of origin can be identified on the mucosa as early as 3 to 4 months in utero. Less commonly, the frontal sinus develops from the anterior ethmoid cells of the infundibulum. Its development is quite variable but the final adult proportions are reached only after puberty. Because the left and right frontal sinuses develop independently, a significant asymmetry between these sinuses can arise in the same individual.<sup>3</sup> This independent development results in more common unilateral aplasia or hypoplasia. The shape, dimensions and limits of the frontal recess are determined by its surrounding structures, and a frontal sinus cannot exist without a recess. When a frontal sinus is agenetic, the contralateral sinus may expand and cross the midline toward the agenetic side, which mimics the presence of bilateral frontal sinuses.<sup>3</sup> Replacing the agenetic frontal sinus with the contralateral sinus ensures the proper drainage system and an as-

ymptomatic presentation of this anomaly. Furthermore, it is not known if the craniofacial changes and asymmetries are determined by real bone asymmetry, or if they appeared as a compensatory mechanism.<sup>11,12</sup> The sphenoid sinus reaches its maximum size by the late teenage years, but shows variation in pneumatization. Previous case reports have shown that agenesis of the sphenoid sinus occurs in 1–1.5 % of the population.<sup>13</sup> One of the most common possible results of sphenoid sinus aplasia or agenesis is chronic headache. On the other hand, sphenoid sinus agenesis does not result in facial asymmetry. The maxillary sinus is the first sinus to develop and is usually found to be less pneumatized in the early years of life. Hypoplasia of the maxillary sinus is quite uncommon and often misdiagnosed as chronic sinusitis or neoplasm and is seen unilaterally in 7 % and bilaterally in 2 % of adults.<sup>2</sup> It has been reported in 1.73% to 10.4% of patients with sinus symptoms.<sup>11</sup> However, it is sometimes asymptomatic and is diagnosed using radiological evaluation. Maxillary sinus hypoplasia (MSH) is classified into three types. Type 1 MSH shows mild maxillary sinus hypoplasia, type 2 shows significant sinus hypoplasia with a narrowed infundibular passage and hypoplastic or absent uncinate process, and type 3 is cleft-like maxillary sinus hypoplasia with an absent uncinate process.<sup>14–16</sup> Possible aplasia or hypoplasia maxillary sinus can due to facial changes, especially in the infraorbital area and in dental arch development.<sup>17</sup> Findings such as uncinate process abnormality, orbital enlargement, sphenomaxillary plate, canine fossa elevation, infraorbital fissure enlargement, thickening of the sinus wall and mucosal pathologies can be seen together with maxillary sinus anomalies.<sup>18</sup>

## Summary and Conclusions

In conclusion, the low percentage of the frontal sinus agenesis must be taken into consideration during the pre-surgical planning related to the sinus.<sup>19</sup> Therefore, analysing DVT images of the frontal sinus is a useful tool to identify its size and configuration and to minimize the risk factors associated with surgical procedures.<sup>20</sup> Chronic headache, sinusitis and asymmetric craniofacial changes can be associated with paranasal sinus anomalies, but these abnormalities can be asymptomatic for many years.

## References

1. Güven DG, Yilmaz S, Ulus S, Subaşı B. Combined aplasia of sphenoid, frontal, and maxillary sinuses accompanied by ethmoid sinus hypoplasia. *J Craniofac Surg.* 2010;21:1431-3.
2. Khanduri S, Singh N, Bhadury S, Ansari AA, Chaudhary M. Combined Aplasia of Frontal and Sphenoid Sinuses with Hypoplasia of Ethmoid and Maxillary Sinuses. *Indian J Otolaryngol Head Neck Surg.* 2015;67:434-7.

3. Çakur B, Sumbullu MA, Durna NB. Aplasia and agenesis of the frontal sinus in Turkish individuals: a retrospective study using dental volumetric tomography. *Int J Med Sci.* 2011;8:278-82.
4. Gotlib T, Kuźmińska M, Held-Ziółkowska M, Osuch-Wójcikiewicz E, Niemczyk K. Hidden unilateral aplasia of the frontal sinus: a radioanatomic study. *Int Forum Allergy Rhinol.* 2015;5:441-4.
5. Ozgursoy OB, Comert A, Yorulmaz I, Tekdemir I, Elhan A, Kucuk B. Hidden unilateral agenesis of the frontal sinus: human cadaver study of a potential surgical pitfall. *Am J Otolaryngol.* 2010;31:231-4.
6. Danesh-Sani SA, Bavandi R, Esmaili M. Frontal sinus agenesis using computed tomography. *J Craniofac Surg.* 2011;22:48-51.
7. Aydinlioğlu A, Kavakli A, Erdem S. Absence of frontal sinus in Turkish individuals. *Yonsei Med J.* 2003;44:215-8.
8. Ozcan KM, Hizli O, Sarisoy ZA, Ulusoy H, Yildirim G. Coexistence of frontal sinus hypoplasia with maxillary sinus hypoplasia: a radiological study. *Eur Arch Otorhinolaryngol.* 2018;275:931-5.
9. Pifferi M, Bush A, Caramella D, et al. Agenesis of paranasal sinuses and nasal nitric oxide in primary ciliary dyskinesia. *Eur Respir J.* 2011;37:566-71.
10. Spaeth J, Krugelstein U, Schlondorf G. The paranasal sinuses in CT-imaging: development from birth to age 25. *Int J Pediatr Otorhinolaryngol.* 1997;39:25-40.
11. Teodorescu E, Crişan M, Țărmure V, Galan E, Milicescu Ş, Ionescu E. Upper airway cavities morphologic features in facial asymmetries. *Rom J Morphol Embryol.* 2015;56:579-83.
12. Natsis K, Karabatakis V, Tsikaras P, Chatzibalas T, Stangos A, Stangos N. Frontal sinus anatomical variations with potential consequences for the orbit. Study on cadavers. *Morphologie.* 2004;88:35-8.
13. Değirmenci B, Haktanır A, Acar M, Albayrak R, Yücel A. Agenesis of sphenoid sinus: three cases. *Surg Radiol Anat.* 2005;27:351-3.
14. Khanduri S, Agrawal S, Chhabra S, Goyal S. Bilateral maxillary sinus hypoplasia. *Case Rep Radiol.* 2014:148940.
15. Tasar M, Cankal F, Bozlar U, Hidir Y, Sağlam M, Ors F. Bilateral maxillary sinus hypoplasia and aplasia: radiological and clinical findings. *Dentomaxillofac Radiol.* 2007;36:412-5.
16. Erdem T, Aktas D, Erdem G, Miman MC, Ozturan O. Maxillary sinus hypoplasia. *Rhinology.* 2002;40:150-3.
17. Jafari-Pozve N, Sheikhi M, Ataie-Khorasgani M, Jafari-Pozve S. Aplasia and hypoplasia of the maxillary sinus: A case series. *Dent Res J (Isfahan).* 2014;11:615-7.
18. Selcuk A, Ozcan KM, Akdogan O, Bilal N, Dere H. Variations of maxillary sinus and accompanying anatomical and pathological structures. *J Craniofac Surg.* 2008;19:159-64.
19. Rege IC, Sousa TO, Leles CR, Mendonça EF. Occurrence of maxillary sinus abnormalities detected by cone beam CT in asymptomatic patients. *BMC Oral Health.* 2012 10;12:30.
20. Lorkiewicz-Muszyńska D, Kociemba W, Rewekant A, et al. Development of the maxillary sinus from birth to age 18. Postnatal growth pattern. *Int J Pediatr Otorhinolaryngol.* 2015;79:1393-400.