








CASUISTIC PAPER

Natalia Leksa ^{1(ABDFG)}, Adam Uryniak ^{2(ABDFG)}, David Aebisher ^{3(BDFG)},
David Leksa ^{2(ABDFG)}, Dorota Bartusik-Aebisher ^{4(ABDFG)}

Vascular surgery and an occurrence of stroke

¹ Department of Anatomy, Medical College of Rzeszów University, Rzeszów, Poland

² Rzeszów Center for Vascular and Endovascular Surgery, Rzeszów, Poland

³ Department of Photomedicine and Physical Chemistry, Medical College of Rzeszów University, Rzeszów, Poland

⁴ Department of Biochemistry and General Chemistry Medical College of Rzeszów University, Rzeszów, Poland

ABSTRACT

Introduction. The brain responds to metabolic disorders with a limited array of symptoms and signs. The brain has enormous needs in terms of substrate and blood flow.

Aim. This paper presents a case report reporting episode of stroke.

Description of the case. The incidence of cerebral vascular episodes in the form of strokes, transient episodes of cerebral ischemia is reported.

Conclusion. The chemical constituency of the brain are generally quite different from those of other tissues. Stroke is a clinical syndrome characterized by sudden focal or generalized brain dysfunction.

Keywords. cerebral arteries, diagnosis, stroke

Introduction

There are many systematic medical illnesses that can affect the central nervous system. These include such common affiliation as diabetes, heart failure, cirrhosis of the liver, and chronic obstructive pulmonary disease. There is however a subgroup of medical illness that has major and important systematic manifestation in the central nervous system. These disorders can and most certainly do affect other bodily systems but the central nervous system manifestation are such that serious that serious injury, disability or even death can result. Stroke is the third most common cause of rubbish after heart disease and cancer today. The incidence

of stroke is an infarct of a portion of the brain, most often secondary to occlusion of a major or minor blood vessel. The sequelae of a particular stroke depend to a large extent on the location of the blood vessel the extent of tissue damage and the collateral circulation. As a sequela of stroke there is tissue death of a portion of the brain. Within the initial few hours after a stroke and for a period perhaps 1 to 3 days there will be variable but progressive tissue edema and death in the area around the zone of infraction that is partially fed by the occluded vessel. Stroke is one of the main causes of mobility impairment and the second most common cause of dementia.¹⁻³ Discomfort persists over 24

Corresponding author: Natalia Leksa, e-mail: leksanatalia@gmail.com

Participation of co-authors: A – Author of the concept and objectives of paper; B – collection of data; C – implementation of research; D – elaborate, analysis and interpretation of data; E – statistical analysis; F – preparation of a manuscript; G – working out the literature; H – obtaining funds

Received: 1.04.2020 | Accepted: 31.05.2020

Publication date: September 2020

hours or leads to death with no cause other than cerebral. However, if the ailments persist for less than 24 hours and disappear spontaneously, we are talking about TIA (transient ischemic attack) - a transient episode of cerebral ischemia.⁴⁻⁶ Diagnostics primarily includes assessing cardiovascular fitness by measuring blood pressure, ruling out cardiac arrhythmias (Holter RR, Holter ECG, echocardiography), atherosclerosis of the cerebral arteries (duplex carotid ultrasound and transcranial ultrasound) and laboratory tests (glycemia, parameters renal, lipids profile assessment and others).⁷⁻¹⁰ In patients, an abrupt fall in blood pressure may induce cerebral ischemia, sometimes resulting in stroke.¹¹ The fundamental therapy for the treatment of ischemic -hypoxic injury is to correct the cause. May other therapies have been advocated for brain injury of hypoxic ischemic region. None has been found to restore function without neurologic deficit. It has been thought that osmotic diuretics might be successful in case of brain swelling after hypoxic injury.¹²⁻¹⁶ It is recognized that at the time of ischemic hypoxic injury there is often an associated loss of autoregulation of cerebral circulation such that further injury may be indicated. Many patients are initially misdiagnosed and are felt to have primary cerebral pathology, such as subdural hematoma. In the hyponatremic patients the diagnosis must be made on clinical grounds but appears to be the most likely cause of the relapsing encephalopathy, with either death or a persistent vegetative state as the usual outcome.¹⁷ In the last years there have been a large number of studies of patients with hyponatremia who have developed cerebral demyelinating lesions. Some of these investigators have suggested an association between hyponatremia or its therapy and central pontine myelinolysis. Cerebral demyelination occurring in hyponatremic subjects is usually secondary to a combination of anoxia-hypoxia and increased intracranial pressure. The clinical manifestation is sometimes delayed until after treatment has been completed giving a false appearance of some relationship between cerebral demyelination and the therapy of hyponatremia. Calcium channel blockers has been proposed as a treatment for hypoxic ischemic brain injury based on the hypothesis discussed above that calcium loading of cells leads to necrosis.¹⁸⁻²⁵ The brain depends on a stable internal environment for optimal function. To some extent the other systems in the body serve the brain. They provide nutrients to the brain, remove products of metabolism from the brain and protect the brain from external perturbations.¹⁷⁻²⁰

Aim

The goal of this study was to presents diagnosis and treatment of the stroke.

Description of the case

A 68-year-old patient was admitted to the Department of Neurology because of severe dizziness with nausea, feeling of numbness and weakening of the muscular strength of the right upper limb, which has persisted since morning hours. In the history of nicotine, otherwise not treated chronically.

The admission neurological examination revealed: conscious, verbal contact, full orientation, meningeal and root symptoms, nystagmus, isochoric, in the cranial nerve area: no abnormalities, in the limb area: discrete global paresis of the right upper limb, otherwise without irregularities, deep correct symmetrical reflexes, bilateral correct reflexes. Imaging (CT of the head and MR of the head) imaged fresh ischemic lesions of the left hemisphere of the brain. For the diagnosis of cerebral vascular episodes, an ultrasound examination of the brain vessels was performed, in which 80% of the left internal carotid artery stenosis was described. Diagnosis was extended to an CT scan of the intracerebral arteries, which confirmed the above stenosis (Figure 1).

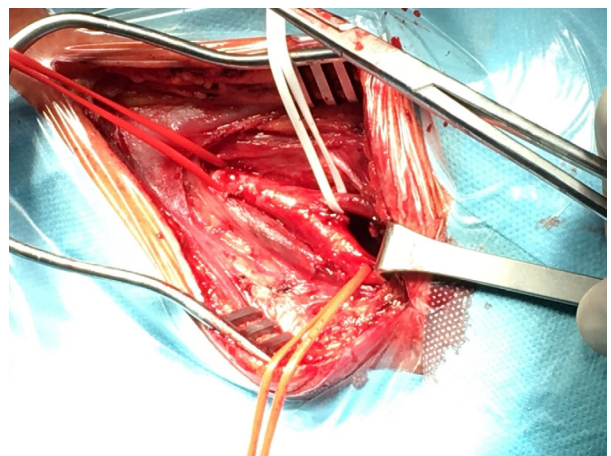


Fig. 1. The vascular surgery by the classical method – endarterectomy

The patient was transferred for further treatment to the Department of Vascular Surgery, where he was operated by the classical method - endarterectomy.

Discussion

Due to the fact that one of the main causes of stroke is the narrowing of the intracerebral arteries caused most often by atherosclerotic plaques, each patient after an episode of stroke or after an episode of transient cerebral ischemia should have an ultrasound examination of the intracerebral arteries and a transcranial ultrasound. If any of these methods is not possible, then computed tomography angiography or magnetic resonance angiography are routinely performed.¹ These methods allow the assessment of flow velocity, the ratio of velocity at the stenosis site to the velocity outside the stenosis

and assessment of the plaque morphology (echogenicity, surface, ulceration).⁵ The degree of narrowing can be assessed in a variety of ways, but the NASCET (North American Symptomatic Carotid Endarterectomy Trial) method is most commonly used. About 10-15% of strokes are caused by carotid stenosis, but they are not always symptomatic. Symptomatic stenosis is one where symptoms occur up to 6 months after falling ill, while asymptomatic for more than 6 months. The analyzed patient developed symptomatic stenosis. Due to the location of the atherosclerotic plaque restricting blood flow through the vessel, the method of classical surgery, i.e. endarterectomy (CEA), was decided - Figure 2.

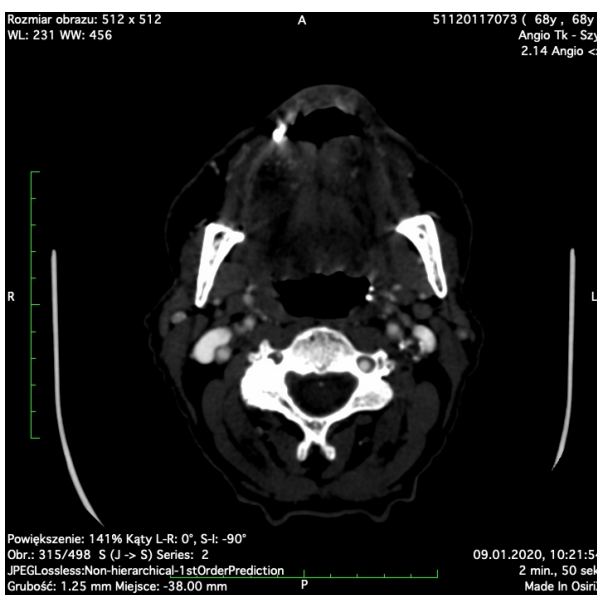


Fig. 2. An MRI picture imaged fresh ischemic lesions of the left hemisphere of the brain

According to current guidelines, this method is preferred in patients with minor neurological symptoms, male, with cortical and hemispheric symptoms, and with concurrent internal load and age over 70 years. The above patient met most of these criteria. The second possible method of intracerebral artery surgery is CAS (carotid stenting), which involves the implantation of a stent within a diseased vessel with access usually through the femoral artery. CAS has an advantage over CEA in the following cases: previous radiotherapy of the area, recurrent stenoses, recurrent laryngeal nerve palsy, difficult surgical access (stenoses located very high within the internal carotid artery). In the study Carotid Revascularization Versus Stenting Trial (CREST), Endarterectomy Versus Angioplasty in Patients with Symptomatic Severe Carotid Stenosis (EVA-3S), Stent Protected Angioplasty Versus Carotid Endarterectomy (SPACE) and International Carotid Stenting Study (ICSS) associated with 30-day risk stroke in connection with surgery using the CEA or CAS method, it was proved that a sig-

nificantly lower risk was associated with the surgery using the classical endarterectomy method.⁶ It should also be noted that in patients operated on by the CEA method - it is recommended to use acetylsalicylic acid chronically after surgery or in the case of resistance to clopidogrel. However, in the case of CAS-acetylsalicylic acid surgery together with 1. however, clopidogrel therapy should not be longer than 3 months. stroke is a complex clinical picture caused by extreme elevation of body temperature.²⁰⁻²⁵

Conclusion

Due to the high incidence of cerebral vascular episodes in the form of strokes, transient episodes of cerebral ischemia, detailed diagnosis of the causes of the disease in each of the above cases is necessary. For symptomatic carotid stenosis, the only effective method is the surgical method. The choice of surgical method due to the location of the atherosclerotic plaque, concomitant diseases and general condition of the patient always belongs to the vascular surgeon.

References

1. Keigher KM. Large Vessel Occlusion in the Acute Stroke Patient: Identification, Treatment, and Management. *Crit Care Nurs Clin North Am.* 2020;32(1):21-36.
2. Ferrer Pastor M, Iñigo Huarte V, Juste Díaz J, Goiri Noguera D, Sogues Colom A, Cerezo Durá M. Systematic review of the treatment of spasticity in acquired adult brain damage. *Rehabilitacion (Madr).* 2020;54(1):51-62.
3. Stinear CM, Lang CE, Zeiler S, Byblow WD. Advances and challenges in stroke rehabilitation. *Lancet Neurol.* 2020. pii: S1474-4422(19)30415-6.
4. Krishnan K, Bassilious K, Eriksen E, Bath PM, Sprigg N, Brækken SK, Ihle-Hansen H, Horn MA, Sandset EC. Posterior circulation stroke diagnosis using HINTS in patients presenting with acute vestibular syndrome: A systematic review. *Eur Stroke J.* 2019;4(3):233-239.
5. Cattaneo G, Meckel S. Review of selective brain hypothermia in acute ischemic stroke therapy using an intracarotid, closed-loop cooling catheter. *Brain Circ.* 2019;5(4):211-217.
6. Brown JM, Everett BM. Cardioprotective diabetes drugs: what cardiologists need to know. *Cardiovasc Endocrinol Metab.* 2019;8(4):96-105.
7. MacManus JP, Buchan AM. Apoptosis after experimental stroke: fact or fashion? *J Neurotrauma.* 2000;17(10):899-914.
8. Small DL, Morley P, Buchan AM. Biology of ischemic cerebral cell death. *Prog Cardiovasc Dis.* 1999;42(3):185-120.
9. Knight-Greenfield A, Nario JJQ, Gupta A. Causes of Acute Stroke: A Patterned Approach. *Radiol Clin North Am.* 2019;57(6):1093-1108.
10. Barow E, Thomalla G. Acute treatment of ischemic stroke : Current standards. *Nervenarzt.* 2019;90(10):979-986.

11. Jansen PA, Schulte BP, Meyboom RH, Gribnau FW. Anti-hypertensive treatment as a possible cause of stroke in the elderly. *Age Ageing*. 1986;15(3):129-138.
12. Neill J, Lin CH. A Review of Transcatheter Closure of Patent Foramen Ovale. *Methodist Debaquey Cardiovasc J*. 2017;13(3):152-159.
13. Hoskins MH, Patel AM, DeLurgio DB. Left Atrial Appendage Occlusion, Shared Decision-Making, and Comprehensive Atrial Fibrillation Management. *Interv Cardiol Clin*. 2018;7(2):267-283.
14. Miranda JJ, Moscoso MG, Yan LL, Diez-Canseco F, Málaga G, Garcia HH, Ovbiagele B. Addressing post-stroke care in rural areas with Peru as a case study. Placing emphasis on evidence-based pragmatism. *J Neurol Sci*. 2017;375:309-315.
15. Kanarek SE, Wright P, Liu J, et al. J Multiple fibroelastomas: a case report and review of the literature. *Am Soc Echocardiogr*. 2003;16(4):373-376.
16. Touzé E, Gauvrit JY. Natural history of cervical arterial dissections. Review of the literature and preliminary results from a national study group. *J Neuroradiol*. 2002;29(4):251-256.
17. Richards KC, Hall KS, Shook D, Brown P, Nagel CL. Sleep-disordered breathing and stroke. *J Cardiovas. Nurs*. 2002;17(1):12-22.
18. Meister J, Levy D. Stroke: a case review. *Clin Excell Nurse Pract*. 2000;4(4):212-215.
19. Herzig R, Burval S, Vladyka V, et al. Familial occurrence of cerebral arteriovenous malformation in sisters: case report and review of the literature. *Eur J Neurol*. 2000;7(1):95-100.
20. Berger C, Schwab S. Stroke-a medical emergency. *Eur J Emerg Med*. 1999;6(1):61-69.
21. Bader MK, Prendergast V. Stroke and women. *Crit Care Nurs Clin North Am*. 1997;9(4):477-87.
22. Kajs-Wyllie M. Venous stroke in the pregnant and postpartum patient. *J Neurosci Nurs*. 1994;26(4):204-209.
23. Klonoff DC, Andrews BT, Obana WG. Stroke associated with cocaine use. *Arch Neurol*. 1989;46(9):989-993.
24. Shibolet S, Lancaster MC, Danon Y. Heat stroke: a review. *Aviat Space Environ Med*. 1976;47(3):280-301.
25. Lackland DT, Roccella EJ, Deutsch A, et al. Factors Influencing the Decline in Stroke Mortality: A Statement from the American Heart Association/American Stroke Association. *Stroke*. 2014;45(1):315-353.