



## CASUISTIC PAPER

Katarzyna Fuksa 

# The importance of electroencephalography in the diagnosis of hepatic encephalopathy due to cirrhosis – a case report

Department of Neurology, MSWiA Hospital in Rzeszow, Rzeszow, Poland

### ABSTRACT

**Introduction and aim.** Hepatic encephalopathy (HE) associated with cirrhosis of the liver is a neuropsychiatric syndrome, with symptoms ranging from barely detectable changes to deep coma. It frequently occurs in the form of episodes and relapses and can be triggered by external factors. HE severity is graded according to the West Haven criteria. The aim of the study is to draw attention to the ever-important and often key role of electroencephalography in the diagnosis of hepatic encephalopathy, even in today's era of increasingly advanced diagnostic methods.

**Description of the case.** A 57-year-old patient, professionally active at the time, was admitted to the hospital's Neurology Department on an emergency basis due to difficulties with standing and moving, orientation disorders and limb tremor.

**Conclusion.** While HE pathogenesis is multifactorial, the most important factors include increased brain exposure to ammonia, intestinal dysbiosis, and endotoxemia inducing a systemic inflammatory response. Patient observation, blood laboratory tests, neuropsychological tests and neurophysiological tests (EEG and evoked potentials) play an important role in establishing the diagnosis. Treatment and secondary prevention of hepatic encephalopathy include elimination of triggers and reduction of ammonia production and improvement of its metabolism.

**Keywords.** ammonia, cirrhosis, electroencephalography, encephalopathy, triphasic waves

**Abbreviations:** EEG – electroencephalography, HE – hepatic encephalopathy, MRI – magnetic resonance imaging, CT – computed tomography

### Introduction

Hepatic encephalopathy (HE) is one of major complications of liver cirrhosis, dramatically impairing the general condition of cirrhotic patients and increasing the risk of death due to hepatic causes. Upon diagnosis of cirrhosis, HE is present in 10-14 of patients, while the risk of the first episode occurring within 5 years is 5-25%.<sup>1,2</sup> During cirrhosis decompensation, ECT is diagnosed in 16-21% of cases. Improvement in liver function usually leads to regression of HE symptoms, although neuropsychiatric changes may sometimes become per-

manent.<sup>3</sup> The condition was first described in 1893 by Nencki, Pavlov and Zaleski, who found ammonia imbalance caused by portal-systemic anastomosis in dogs to be the reason for neurobehavioral changes (aggression, irritability, ataxia, convulsions and coma).<sup>4</sup>

Ammonia is produced in the intestines through the bacterial metabolism of amines, amino acids, purines and urea. It is produced in smaller amounts in the intestinal epithelium. Under physiological conditions, ammonia that has entered the bloodstream is largely metabolised by the liver; trace amounts of ammonia are metabolised by the skeletal muscles and the brain. Ammonia is converted to urea in the hepatocytes of the peripheral zone of the hepatic lobe, Krebs cycle, and to glutamine in the hepatocytes of the central zone of the

**Corresponding author:** Katarzyna Fuksa, e-mail: [katarzfuk@gmail.com](mailto:katarzfuk@gmail.com)

Received: 10.02.2022 / Revised: 25.02.2022 / Accepted: 27.02.2022 / Published: 30.06.2022

Fuksa K. *The importance of electroencephalography in the diagnosis of hepatic encephalopathy due to cirrhosis – a case report.* Eur J Clin Exp Med. 2022;20(2):224–231. doi: 10.15584/ejcem.2022.2.12



lobe.<sup>5</sup> In decompensated cirrhosis, the liver's capacity for metabolising ammonia decreases by approximately 80%, while its metabolism by the skeletal muscles and the brain increases accordingly.<sup>6,7</sup>

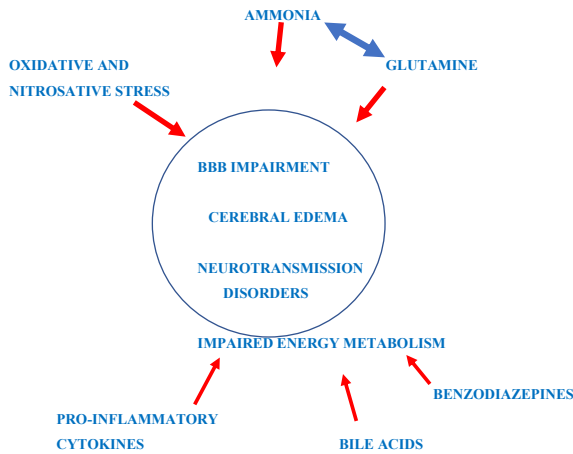


Fig. 1. Disturbances in the circulation of ammonia

As a gaseous substance, ammonia crosses the blood-brain barrier inhibiting cellular membrane potentials and impairing the function of neurotransmitters (Fig. 1). However, ammonia concentration does not correlate with the clinical expression of HE, which suggests involvement of other brain toxic bacterial products, such as mercaptans,  $\gamma$ -aminobutyric acid (GABA), phenols, short- and medium-chain fatty acids and oxindoles.<sup>8,9</sup> The latter, by inhibiting the activity of sodium channels in the brain, may lead to impaired consciousness and coma.

Hepatic encephalopathy covers a whole range of potentially reversible neurological and psychiatric disorders that affect intellectual, cognitive and personality functioning.<sup>10</sup> Patients suffer from, *inter alia*, memory impairment, orientation and concentration disorders,

structural apraxia, behavioural changes (irritability, euphoria) and disturbance of the circadian rhythm of sleep.<sup>11</sup> Neurological examination reveals slowness of movement, dysarthria, coarse tremor and/or pyramidal signs. Impaired consciousness may progress from clouding to deep coma without response to stimuli.<sup>12</sup>

HE has been divided into 5 grades of clinical advancement according to the West Haven classification (Table 1).<sup>13</sup> This division is largely subjective as the transition between subsequent stages is continuous rather than staged.

The simplified West Haven classification divides hepatic encephalopathy into latent and overt forms. The latent form includes minimal hepatic encephalopathy (MHE), but also Grade 1 HE, with discreet consciousness disorders, mood changes, impaired focus, impaired attention and problems with performing simple mathematical operations.<sup>14</sup> Characteristic features of MHE are the absence of abnormal neurological examination and discreet cognitive and attention disorders that can only be detected through a neuropsychological examination. This form occurs in over 50% of patients with liver cirrhosis and its diagnosis requires a series of neuropsychiatric tests, preferably two due to the likelihood of impairment of various cognitive functions.<sup>15</sup>

The first symptoms of overt hepatic encephalopathy are confusion and lower motor activity. Coma may occur frequently within several days. Many patients show characteristic trembling and fluttering of the hands (tremor, asterixis) and have unpleasant mouth odour. Trembling tongue or eyelids are equivalents of asterixis. Asterixis is not specific to HE (it may occur even in patients with impaired kidney function, congestive heart failure, after overdosing of certain drugs or in carbon monoxide poisoning) and is a consequence of loss of nervous system control over the motor activity of skeletal muscles. The handgrip strength in patients with

Table 1. Grading of hepatic encephalopathy according to the West Haven criteria

Grade	State of consciousness	Intellect and behaviour	Neurological findings
0	Normal	No or minimum impairment of memory, intellectual function and motor coordination	Normal examination (no asterixis)
1	Sleep-wake disorders – hypersomnia or insomnia	Shortened attention span Lower intellectual function – impaired addition or subtraction; forgetfulness Irritability; alternating euphoria and depression	Mild asterixis Change of handwriting
2	Disorientation Lethargy and apathy	Slurred speed Significantly impaired intellectual function; personality changes; inappropriate behaviour	Obvious asterixis and shaky hands Dysarthria Weakened tendon reflexes
3	Confusion Somnolent but arousable	Inability to perform intellectual tasks Gross disorientation as to time and place Retrograde amnesia; periodic bouts of rage; delusions; incomprehensive speech	Exaggerated tendon reflexes Babinski reflex Nystagmus; extrapyramidal symptoms
4	Coma with or without response to painful stimuli	Impossible to assess (coma)	Decerebration Dilated pupils not reacting to light

asterixis varies between strong and weak. In addition, patients with HE display extrapyramidal symptoms resembling Parkinson's disease (bradykinesia, slowness of speech, hypomimia, tremor, dyskinesia).<sup>16</sup>

Hepatic myelopathy as a symptom of late-stage cirrhosis may mimic HE. Such patients suffer from motor function disorders that prevail over the neuropsychiatric disorders; they may take the form of spastic paraplegia with exorbitant tendon reflexes. In the event of convulsions, severe hyponatraemia should be excluded in the first instance.<sup>17</sup>

The International Society of Hepatic Encephalopathy and Nitrogen Metabolism recommends diagnosis of overt HE only after appearance of disorientation or coarse hand tremor.<sup>18</sup>

Taking into account the duration of symptoms, clinically evident HE was classified into episodic (symptoms recurring after more than 6 months), recurrent (when the subsequent relapse occurs within 6 months) and chronic. Chronic HE occurs on an ongoing basis but its severity fluctuates. In its induced form, hepatic encephalopathy accounts for about 90% of all cases. The most common HE-inducing factors are bacterial infections, diuretics, bleeding, constipation, electrolyte disturbances or therapeutic paracentesis.<sup>16,19</sup>

Diagnosis of HE is primarily based on the patient's medical history and physical examination to check for typical symptoms, such as metabolic tremor. Laboratory testing comprises basic biochemical tests, including assessment of liver enzymes, blood ammonia concentration, peritoneal puncture fluid test, coagulogram, albumin, as well as neuropsychological and neurophysiological tests (EEG and evoked potentials). EEG may reveal nonspecific changes, such as generalised slowing of basic activity, or abnormalities more typical of HE, such as bilaterally synchronous delta waves and triphasic waves, mainly above the frontal lobes. Sharp waves are superimposed over slow waves in the frontal lobe area or appear in a generalised way. The EEG test results may help diagnosis; however, no correlation has yet been found between severity of the pathology in the EEG test and the clinical advancement of HE.<sup>20,21</sup> Neuroimaging is mainly helpful in differential diagnosis. The brain CT scan result is often correct. Sometimes cerebral edema is found in the acute stage of the disease, and atrophy in the chronic stage. On the other hand, MRI is more sensitive in detecting cerebral edema; it also allows to exclude other cerebral pathologies. Patients with liver cirrhosis frequently display bilateral increase in the signal intensity within the globus pallidus, possibly caused by manganese deposits; the signal intensity does not correlate with the clinical advancement of the disease. MRI spectroscopy can show an increase in concentration of the osmotically active agents of the brain, such as myoinositol, glutamate/glutamine and choline.<sup>22</sup>

Due to the lack of specific diagnostic tests, the diagnosis of HE requires exclusion of neurological and metabolic diseases unrelated to cirrhosis.<sup>23,24</sup> HE treatment relies on reducing intestinal ammonia production (lactulose, rifaximin, probiotics) and improving its metabolism (L-ornithine-L-aspartate, branched-chain amino acids).<sup>25</sup>

### Aim

The aim of the study is to draw attention to the ever-important and often key role of electroencephalography in the diagnosis of hepatic encephalopathy, even in today's era of increasingly advanced diagnostic methods.

### Description of the case

A 57-year-old patient, professionally active at the time, was admitted to the hospital's Neurology Department on an emergency basis due to difficulties with standing and moving, orientation disorders and limb tremor. The symptoms had appeared two days before. In 2015, she was diagnosed with alcoholic cirrhosis of the liver, grade 2 esophageal varices, thrombocytopenia and arterial hypertension. She had a history of alcohol abuse but according to the patient and her family she had been abstinent for 6 months. Upon admittance she was conscious, with psychomotor slowing, oriented about herself and her location but disoriented as to time; she was able to follow simple instructions. Neurological examination showed no meningeal symptoms; other symptoms included speech dysarthria; no paresis; ataxia of the trunk and limbs; coarse positional tremor of the upper limbs; decreased muscle tone in four limbs; uncertain gait, wide-based, requiring assistance. The CT scan of the head revealed a chronic ischemic vascular lesion in the left frontal lobe, with no freshly extravasated blood or other focal lesions. The USG test of the abdominal cavity showed no liver enlargement; the liver was of uneven outline and small nodular appearance, and had normal echogenicity. The pancreas showed no enlargement and had reduced echogenicity suggesting chronic inflammatory changes; the spleen was enlarged and had a homogeneous structure and normal echogenicity. The venous vessels in the splenic hilum were dilated. No free fluid in the peritoneal cavity was noted. Basic laboratory blood tests revealed an increased bilirubin level of 2.2 mg/dL [normal range 0.2-1.2 mg/dL], a slightly elevated liver enzymes concentration with GGT of 57 U/L [normal range 9-36 U/L] and AST of 36 U/L [normal range 5-34 U/L], and a decreased albumin level of 3.2 g/dL [normal range 3.5-5.2 g/dL].

During the second day of stay improvement of the patient's condition was noted, with reduction of limb tremors, improvement of gait and correct orientation. The patient did not report any significant complaints.

Diagnostic tests were extended to include head MRI and EEG test. MRI showed numerous foci suggesting

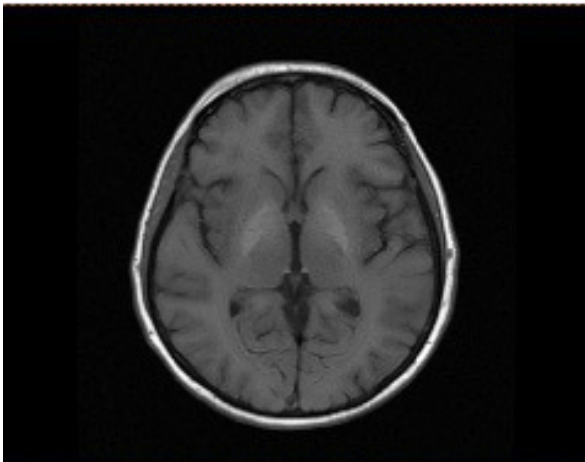


Fig. 2. MRI T1

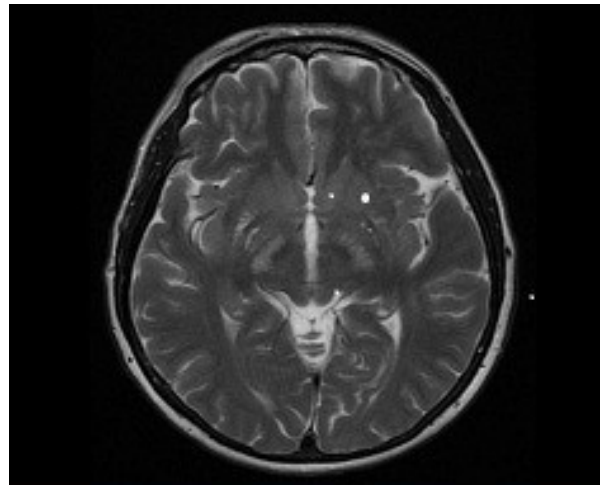


Fig. 3. MR T2

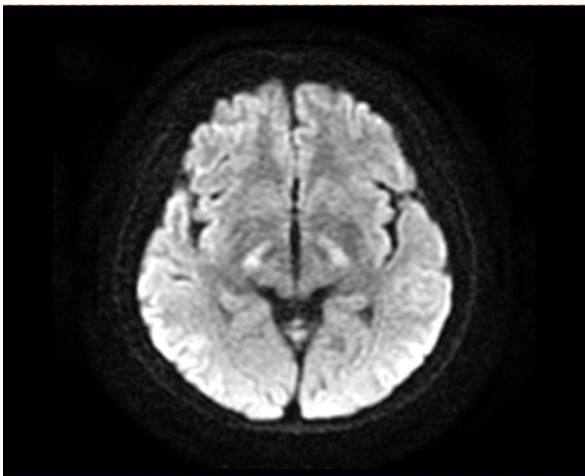


Fig. 4. MR DWI

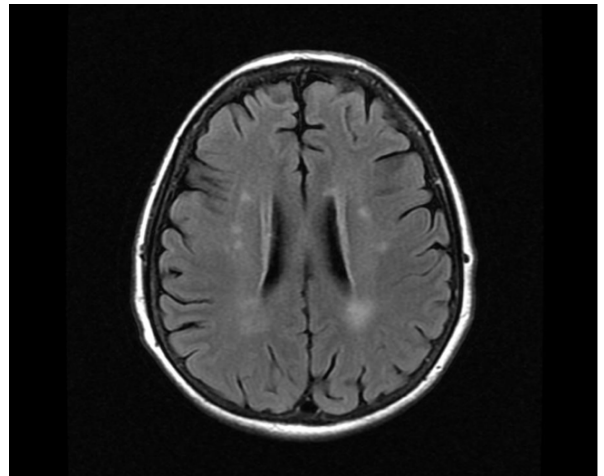


Fig. 5. MR FLAIR

chronic hypoxic-ischemic changes; in the globus pallidus, ventrolateral thalamus and substantia nigra and the brain branches, symmetrical banded foci were noted on both sides with higher signal intensity at T1- and T2-weighted imaging, and the FLAIR and DWI sequences (with no water diffusion restrictions) – the image may correspond to the acquired hepatocerebral degeneration in the course of liver cirrhosis (Fig. 1-4).

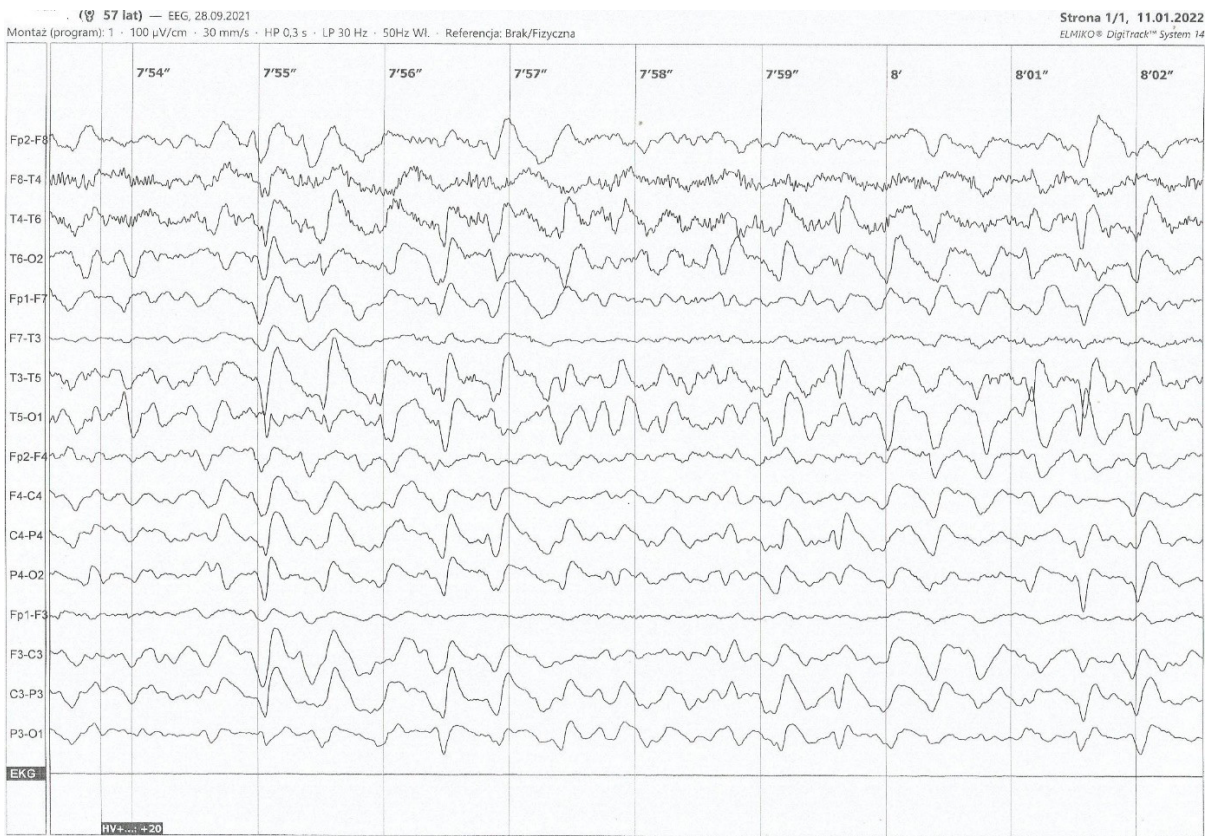
The EEG recording showed synchronous and symmetrical biphasic and triphasic waves and complexes of sharp and slow waves against the backdrop of generalised slowing of basic activity. For stop signals, HV and FS the notation pattern remained unchanged (Fig. 6 and 7).

The patient was subjected to psychological assessment (4<sup>th</sup> day of stay); at the time of the assessment, she was fully oriented, in good logical verbal contact and in a mood adequate to her disease situation. In order to assess the patient's cognitive performance in a more detailed way, further examination by mental health specialists was recommended. Additionally, the patient was

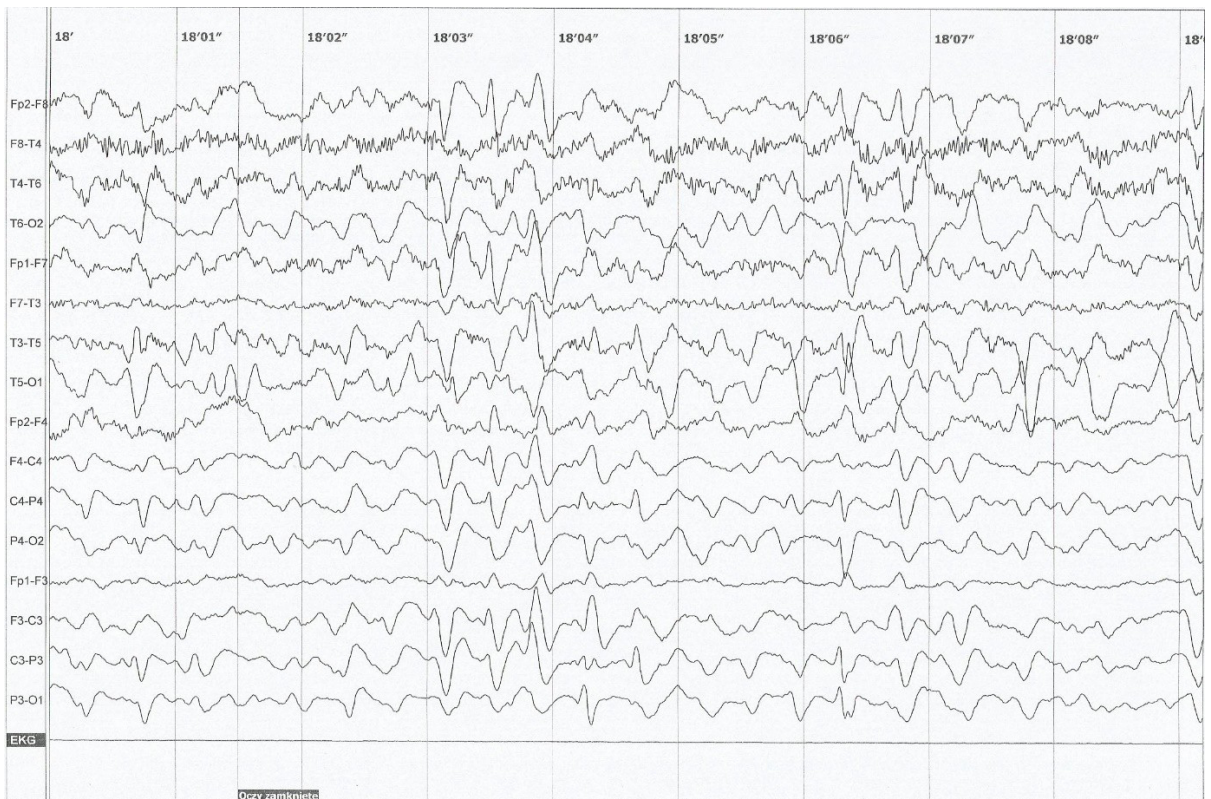
consulted by a speech therapist (assessment on the 3<sup>rd</sup> day of stay), where she appeared conscious, in logical verbal contact and correctly oriented. The patient's verbal perception and expression were undisturbed, and her voice was low, dull and discreetly dysphonic.

The patient's ammonia concentration was determined and hyperammonaemia was found (128.65  $\mu\text{mol/l}$ ; normal range 18-72  $\mu\text{mol/l}$ ). In connection with cognitive impairment upon admission and changes in EEG, the patient was diagnosed with overt hepatic encephalopathy. The treatment included use of Lactulose and Xifaxan yielding further improvement.

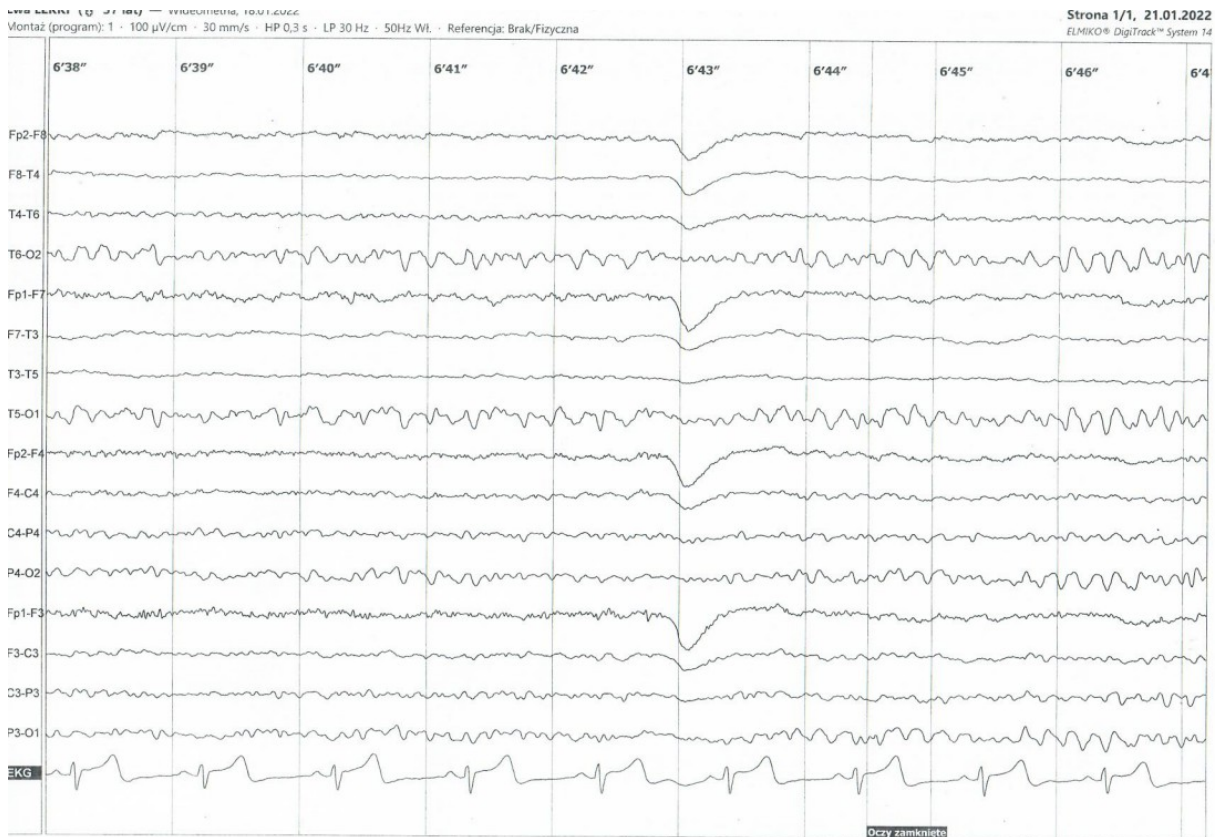
In October 2021, the patient again experienced disturbed consciousness after the night, with weakness and imbalance preventing movement. At that time, she was hospitalised at the Neurology Department, where biochemical tests also revealed hyperammonaemia (ammonia 210  $\mu\text{g/dL}$ ; normal range 19-54  $\mu\text{g/dL}$ ); MRI was comparable to the September 2021 results. The EEG recording showed polymorphic slow delta waves as well as symmetrical and synchronous biphasic and triphasic



**Fig. 6.** Synchronous medium and high voltage biphasic and triphasic waves and complexes of sharp and slow waves visible against the background of generalised slowing of basic activity



**Fig. 7.** EEG recording (cont.)



**Fig. 8.** Follow-up EEG test after 3 months. Slowed-down spatially differentiated EEG recording

waves against the backdrop of disoriented and slower basic activity. The patient was discharged with improvement.

The EEG follow-up test performed after 3 months on an outpatient basis at the Neurological Clinic of the local hospital showed improvement of the recording: the basic activity continued to be slowed down; however, delta waves as well as biphasic and triphasic waves were not visible (Fig. 8).

The patient was in logical verbal contact; deviations included slightly wide-based gait.

## Discussion

Changes in the EEG recording in cirrhotic patients were described in the 1950s.<sup>21</sup> The main exponent of HE is generalised slowing of function. Furthermore, posterior dominant rhythm is disturbed, slowed down or absent. Depending on the severity of HE and the degree of consciousness impairment, the slowing may be mild or very severe; it is usually symmetrical unless the pathology is originated from focal lesions unrelated to the disease. In such cases, features of focal and generalised slowing may be visible simultaneously.<sup>12,13</sup>

The degree of slowing of basic activity usually correlates with serum ammonia concentration and liver damage severity. EEG changes occur in both full-blown and minimal hepatic encephalopathy and are particularly useful for guiding diagnosis of poorly expressed symp-

toms.<sup>26</sup> At an early stage of the disease, lower-frequency alpha waves with diffused theta waves are visible in the frontal and temporal lobes, or in all leads.<sup>27</sup> As the clinical condition deteriorates, theta waves and subsequently delta waves begin to prevail in the recording.<sup>21</sup> For patients in deep coma, a gradual decrease in wave frequency and amplitude is observed up to disappearance of EEG activity.<sup>28,29</sup>

An important element of EEG changes in HE is the presence of periodically occurring triphasic waves. The concept of triphasic was first introduced by Bickford and Butt in 1955.<sup>30,31</sup> These are medium- to high-voltage sharp waves or delta waves with a sharp pattern and triphasic morphology: a positive sharp wave preceded and followed by a negative potential of lower amplitude. The wave frequency is 1-3 Hz and the waves usually appear in a series against the backdrop of slow basic activity. Sharp waves are superimposed over slow waves in the frontal lobe area or appear in a generalised way.<sup>32</sup>

In cases of classic metabolic diseases, triphasic waves show an anterior-posterior delay, which means that the waves appear in the posterior leads with a delay of about 100 ms compared to the frontal leads. The background of the frontal-posterior lag is unknown. Triphasic waves were initially considered pathognomonic of hepatic encephalopathy.<sup>30,32</sup> It is now known that they occur in about 25% of patients with HE but they can also accompany other metabolic encephalopathies, especially ure-

mic and hypoxic encephalopathies as a result of cardiac arrest, after intoxication with drugs (e.g. baclofen, lithium, levodopa), hypothyroidism or hyperthyroidism, electrolyte disorders, encephalitis, Alzheimer's disease and CJD.

## Conclusion

In the presented case, the final diagnosis of hepatic encephalopathy required electroencephalographic examination, as the initial diagnosis was ambiguous due to rapid improvement of the patient's condition. By presenting this particular case of hepatic encephalopathy, I would like to emphasise that as a diagnostic method that has been applied for many years, electroencephalographic examination continues to be an important and often key tool in determining the final diagnosis even in today's era of increasingly advanced diagnostic techniques.

## Declarations

### Funding

This research received no external funding.

### Author contributions

Conceptualization, K.F.; Methodology, K.F.; Investigation, K.F.; Resources, K.F.; Writing – Original Draft Preparation, K.F.; Writing – Review & Editing, K.F.; Supervision, K.F.; Project Administration, K.F.

### Conflicts of interest

The authors declare no conflict of interest.

### Data availability

The data sets used and/or analysed during the current study are available from the corresponding author upon reasonable request.

### Ethics approval

Informed consent was obtained from the patient.

## References

1. Elwir S, Rahimi RS. Hepatic Encephalopathy: An Update on the Pathophysiology and Therapeutic Options. *J Clin Transl Hepatol*. 2017;5(2):142-151. doi:10.14218/JCTH.2016.00069
2. Ridola L, Riggio O, Gioia S, Faccioli J, Nardelli S. Clinical management of type C hepatic encephalopathy. *United European Gastroenterology Journal*. 2020;8(5):536-543. doi:10.1177/2050640620909675
3. The global, regional, and national burden of cirrhosis by cause in 195 countries and territories, 1990–2017: a systematic analysis for the Global Burden of Disease Study 2017. *Lancet Gastroenterol Hepatol*. 2020;5(3):245-266. doi:10.1016/S2468-1253(19)30349-8
4. Shawcross DL, Olde Damink SWM, Butterworth RF, Jalan R. Ammonia and hepatic encephalopathy: the more things change, the more they remain the same. *Metab Brain Dis*. 2005;20(3):169-179. doi:10.1007/s11011-005-7205-0
5. Mohiuddin SS, Khattar D. Biochemistry, Ammonia. In: *StatPearls*. StatPearls Publishing; 2022. Accessed February 20, 2022. <http://www.ncbi.nlm.nih.gov/books/NBK541039/>
6. Yoshida Y, Higashi T, Nouse K, et al. Effects of zinc deficiency/zinc supplementation on ammonia metabolism in patients with decompensated liver cirrhosis. *Acta Med Okayama*. 2001;55(6):349-355. doi:10.18926/AMO/32003
7. Fiati Kenston SS, Song X, Li Z, Zhao J. Mechanistic insight, diagnosis, and treatment of ammonia-induced hepatic encephalopathy. *Journal of Gastroenterology and Hepatology*. 2019;34(1):31-39. doi:10.1111/jgh.14408
8. Aldridge DR, Tranah EJ, Shawcross DL. Pathogenesis of Hepatic Encephalopathy: Role of Ammonia and Systemic Inflammation. *J Clin Exp Hepatol*. 2015;5(Suppl 1):S7-S20. doi:10.1016/j.jceh.2014.06.004
9. Jayakumar AR, Norenberg MD. Hyperammonemia in Hepatic Encephalopathy. *J Clin Exp Hepatol*. 2018;8(3):272-280. doi:10.1016/j.jceh.2018.06.007
10. Ferenci P. Hepatic encephalopathy. *Gastroenterol Rep (Oxf)*. 2017;5(2):138-147. doi:10.1093/gastro/gox013
11. Bruyneel M, Sersté T. Sleep disturbances in patients with liver cirrhosis: prevalence, impact, and management challenges. *Nat Sci Sleep*. 2018;10:369-375. doi:10.2147/NSS.S186665
12. Cordoba J. Hepatic Encephalopathy: From the Pathogenesis to the New Treatments. *ISRN Hepatol*. 2014;2014:236268. doi:10.1155/2014/236268
13. Weissenborn K. Hepatic Encephalopathy: Definition, Clinical Grading and Diagnostic Principles. *Drugs*. 2019;79(Suppl 1):5-9. doi:10.1007/s40265-018-1018-z
14. Stinton LM, Jayakumar S. Minimal hepatic encephalopathy. *Can J Gastroenterol*. 2013;27(10):572-574.
15. Zhan T, Stremmel W. The Diagnosis and Treatment of Minimal Hepatic Encephalopathy. *Dtsch Arztebl Int*. 2012;109(10):180-187. doi:10.3238/arztebl.2012.0180
16. Mandiga P, Foris LA, Bollu PC. Hepatic Encephalopathy. In: *StatPearls*. StatPearls Publishing; 2022. Accessed February 20, 2022. <http://www.ncbi.nlm.nih.gov/books/NBK430869/>
17. Kori P, Sahu R, Jaiswal A, Shukla R. Hepatic myelopathy: an unusual neurological complication of chronic liver disease presenting as quadriparesis. *BMJ Case Rep*. 2013;2013:bcr2013009078. doi:10.1136/bcr-2013-009078
18. Hepatic Encephalopathy in Chronic Liver Disease: 2014 Practice Guideline by the European Association for the Study of the Liver and the American Association for the Study of Liver Diseases. *Journal of Hepatology*. 2014;61(3):642-659. doi:10.1016/j.jhep.2014.05.042
19. Step by Step: Managing the Complications of Cirrhosis | HMER. Accessed February 20, 2022. <https://www.dovepress.com/step-by-step-managing-the-complications-of-cirrhosis-peer-reviewed-fulltext-article-HMER>

20. Amodio P, Montagnese S. Clinical Neurophysiology of Hepatic Encephalopathy. *J Clin Exp Hepatol*. 2015;5(Suppl 1):60-68. doi:10.1016/j.jceh.2014.06.007
21. Koul R, Maiwall R, Ramalingam A, et al. Role of EEG in Predicting Outcome of Hepatic Encephalopathy Patients. *Neurodiagn J*. 2020;60(4):272-288. doi:10.1080/21646821.2020.1824959
22. Chavarria L, Cordoba J. Magnetic Resonance Imaging and Spectroscopy in Hepatic Encephalopathy. *J Clin Exp Hepatol*. 2015;5(Suppl 1):S69-S74. doi:10.1016/j.jceh.2013.10.001
23. Bleibel W, Al-Osaimi AMS. Hepatic Encephalopathy. *Saudi J Gastroenterol*. 2012;18(5):301-309. doi:10.4103/1319-3767.101123
24. Karanfilian BV, Cheung M, Dellatore P, Park T, Rustgi VK. Laboratory Abnormalities of Hepatic Encephalopathy. *Clin Liver Dis*. 2020;24(2):197-208. doi:10.1016/j.cld.2020.01.011
25. Swaminathan M, Ellul MA, Cross TJ. Hepatic encephalopathy: current challenges and future prospects. *Hepat Med*. 2018;10:1-11. doi:10.2147/HMER.S118964
26. Marchetti P, D'Avanzo C, Orsato R, et al. Electroencephalography in Patients With Cirrhosis. *Gastroenterology*. 2011;141(5):1680-1689.e2. doi:10.1053/j.gastro.2011.06.085
27. Togo M, Kinoshita M. Hepatic encephalopathy revisited: Beyond the triphasic waves. *Clin Neurophysiol*. 2019;130(3):408-409. doi:10.1016/j.clinph.2018.12.003
28. Hawkes ND, Thomas G a. O, Jurewicz A, et al. Non-hepatic hyperammonaemia: an important, potentially reversible cause of encephalopathy. *Postgraduate Medical Journal*. 2001;77(913):717-722. doi:10.1136/pmj.77.913.717
29. Rayi A, Mandalaneni K. Encephalopathic EEG Patterns. In: *StatPearls*. StatPearls Publishing; 2022. Accessed February 20, 2022. <http://www.ncbi.nlm.nih.gov/books/NBK564371/>
30. Emmady PD, Murr N. EEG Triphasic Waves. In: *StatPearls*. StatPearls Publishing; 2022. Accessed February 20, 2022. <http://www.ncbi.nlm.nih.gov/books/NBK557679/>
31. Davies MG, Rowan MJ, Feely J. EEG and event related potentials in hepatic encephalopathy. *Metab Brain Dis*. 1991;6(4):175-186. doi:10.1007/BF00996917
32. van der Rijt CC, Schalm SW. Quantitative EEG analysis and evoked potentials to measure (latent) hepatic encephalopathy. *J Hepatol*. 1992;14(2-3):141-142. doi:10.1016/0168-8278(92)90148-i