











ORIGINAL PAPER

Juliana Roncini Gomes da Costa , Alana Ludemila de Freitas Tavares ,  
Gladson Ricardo Bertolini , Maria Luiza Serradourada Wutzke ,  
Carolina De Toni Boaro , Diego Francis Saraiva Rodriguez , Rose Meire Costa ,  
Lucinéia de Fátima Chasko Ribeiro 

## Histological aspects of whole-body vibration in the knee remobilization of Wistar rats

Universidade Estadual do Oeste do Paraná, Cascavel, Paraná, Brazil

### ABSTRACT

**Introduction and aim.** The knee is one of the joints where immobilization is most used, however, it can cause morphological changes in the joint tissues and is a challenge to be overcome during rehabilitation. Whole-body vibration (WBV) is capable of generating repetitive oscillatory movements, which cause mechanical stimuli that interfere with tissue plasticity. The aim of this study was to analyze the knee morphology of Wistar rats submitted to remobilization with WBV.

**Material and methods.** 32 male rats were used, divided into four groups (n=8): Control Group (G1), Immobilization Group (G2), Immobilized Group and Free Remobilization (G3), Remobilized Group with WBV (G4). For immobilization, a plastered apparatus was used for 15 days. G3 and G4 carried out free remobilization or with WBV, respectively, for 2 weeks. The knee joints were processed for light microscopy.

**Results.** The WBV led to a reduction in the inflammatory infiltrate in the articular cavity and greater presence of adipocytes in the subintima of the synovial membrane.

**Conclusion.** Remobilization with WBV induced a better tissue response in the synovial membrane when compared to free remobilization.

**Keywords.** articular cartilage, knee, synovial membrane, vibration

### Introduction

The practice of any sport is often associated with the development of musculoskeletal injuries, with great impact on the rehabilitation process for the return to the sport, recovery can take from weeks to months.<sup>1</sup> In many cases, as part of the initial treatment of these injuries, the first method used for protection of injured tissues and pain relief is complete immobilization of the joint, being a common practice for the treatment of orthopedic disorders such as sprains, ligament ruptures, muscle injuries, joints and fractures.<sup>2-4</sup>

Immobilization and associated movement restriction may affect bone, muscle and joint composition. Specifically for the joints, immobilization acts on the cartilage inducing its degeneration, including reduction of hydration, alteration of structure and reduction of proteoglycan and chondrocyte synthesis, and decrease of cartilage thickness, which reflects in the decrease of load absorption capacity, and may cause or worsen chondral lesions, leading in the long run to the development of osteoarthritis, some of these alterations being partially reverted to normal values after remobiliza-

Corresponding author: Gladson Ricardo Flor Bertolini, e-mail: gladsonricardo@gmail.com

Received: 4.03.2022 / Revised: 17.03.2022 / Accepted: 20.03.2022 / Published: 30.06.2022

da Costa JRG, de Freitas Tavares AL, Bertolini GR, et al. *Histological aspects of whole-body vibration in the knee remobilization of Wistar rats*. *Eur J Clin Exp Med*. 2022;20(2):159–166. doi: 10.15584/ejcem.2022.2.4.



tion.<sup>5-9</sup> The joint capsule is also affected by immobilization, which promotes morphological changes in the intima and subintima synovial, resulting in decreased synovial fluid production and reduced nutritional supply to the cartilage.<sup>10</sup>

Thus, early rehabilitation is extremely important to recover joint functionality.<sup>2,3</sup> There are numerous forms of remobilization, such as treadmill running, resistance and aquatic exercises.<sup>10-12</sup> However, the search for new therapies that accelerate the regenerative process in remobilization is of great value. In this sense, studies have shown that whole-body vibration (WBV) can act as an anabolic stimulus for various tissues, including the musculoskeletal system.<sup>13-16</sup> Despite their indications, there are still few studies evaluating WBV on joint tissue, as well as in the remobilization process.<sup>17,18</sup>

### Aim

Thus, this study analyzed the morphological responses of the knee of immobilized and remobilized Wistar rats on a vibration platform.

### Material and methods

#### *Ethical approval*

The study was approved by the Ethics Committee on the Use of Animals of the Universidade Estadual do Oeste do Paraná (UNIOESTE), 2729/2014-GRE.

#### *Sample and experimental groups*

The experiment was performed using 32 Wistar rats, with a mean age of 10 weeks and weight of  $177.20 \pm 16.32$  g, kept in an environment with a temperature of  $23 \pm 1^\circ\text{C}$ , with a photoperiod of 12 hours, receiving water and feed ad libitum. The animals were randomly separated into four groups (n=8):

- Control Group (G1): without any kind of intervention;
- Immobilization Group (G2): submitted to the immobilization protocol;
- Group Immobilization/Free Remobilization (G3): submitted to the immobilization and free remobilization protocol;
- Group Immobilization/Remobilization WBV (G4): submitted to the immobilization and remobilization protocol with the use of the vibration platform.

#### *Immobilization protocol*

To perform the immobilization, the animals were anesthetized (xylazine hydrochloride 15 mg/kg and ketamine hydrochloride 80 mg/kg, intraperitoneally) and immobilized with a plaster bandage. The immobilized groups (G2, G3 and G4) had the orthosis molded from the abdominal region, just below the last ribs, following to the right pelvic limb of each animal, being placed in the whole extension of the limb so that it remained in

complete extension of the knee joint as well as, complete plantar ankle flexion. The animals were kept in this position for a period of 15 consecutive days.

#### *Remobilization protocol*

For the remobilization was used a commercial platform of the brand Arktus professional, with frequency of 60 Hz and vibrations with amplitude of 2 mm, for 10 minutes, five days a week, with rest of two days at the end of the week, for 2 weeks, totaling 10 days of training with WBV. A support was used with the purpose of containing the animal during the vibration and enable the animals to exercise simultaneously, which was made of white MDF wood, and allowed to position 8 animals concomitantly, in stalls with 13 cm wide, 19 cm long and 25 cm high. To minimize a possible bias on the positioning of the animals on different areas of the vibratory platform that received less vibration amplitude, a rotation was performed between the stalls in which each day of treatment the animal was housed in a different place from the previous day.<sup>19</sup>

For G3, after the 15 days of immobilization and the removal of the cast bandage, the animals remained in the cage for 15 days receiving water and feed ad libitum.

#### *Morphological analysis*

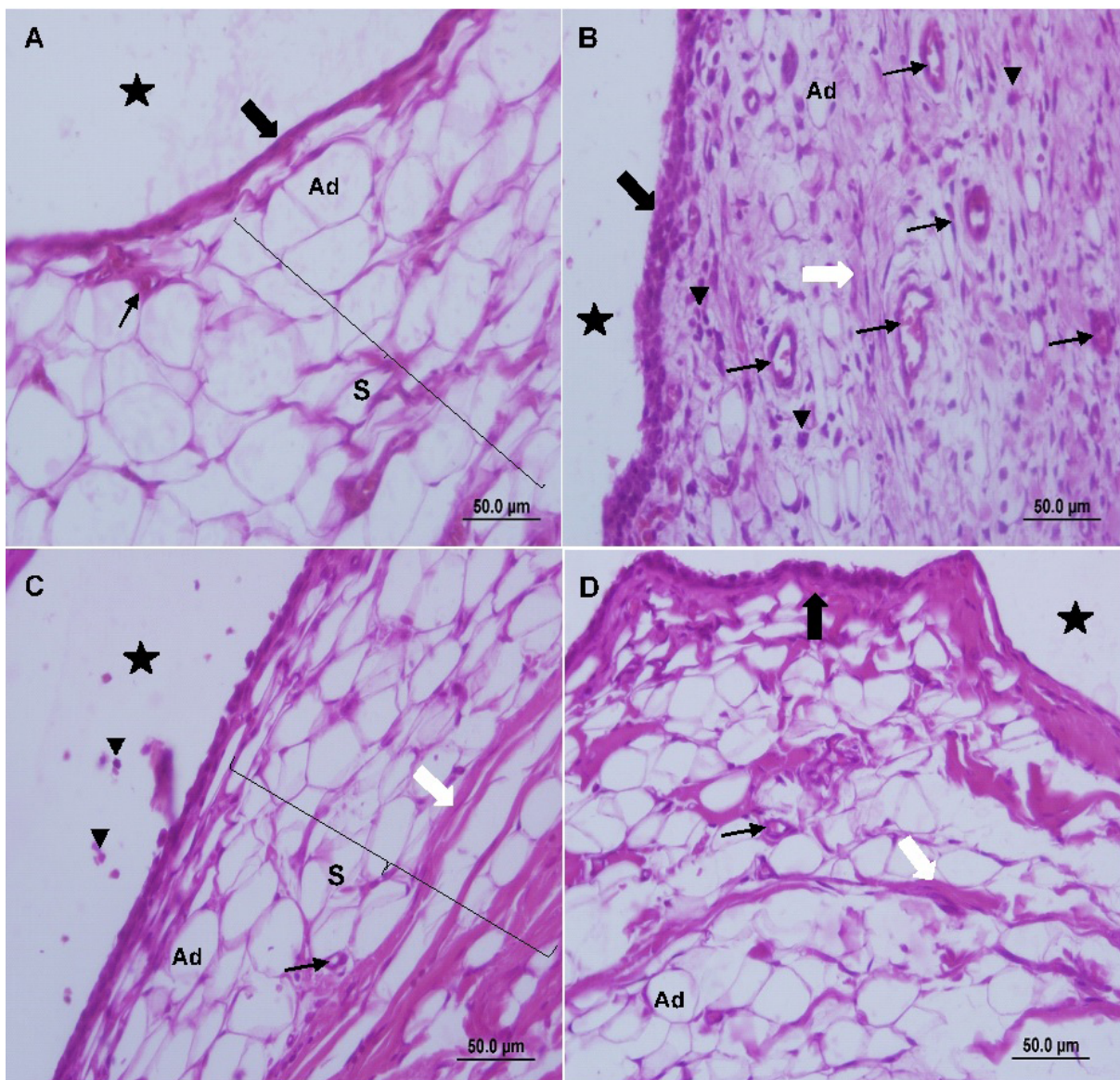
The animals of the control group (G1) and the immobilization group (G2) were eutanasiated soon after the 15 days of intervention, while the animals of the free remobilization group (G3) and the platform remobilization group (G4) were eutanasiated after 2 weeks of remobilization. All the animals were weighed, duly anesthetized by intramuscular injection of 80 mg/kg ketamine and 8 mg/kg xylamine and decapitated in a guillotine. Then the right pelvic limb was dissected and the knee joints followed for histological processing, being fixed in a 10% formaldehyde solution for 24 hours, washed in running water for 1 hour and remaining immersed in 5% trichloroacetic acid for approximately 20 days, following the routine steps for inclusion in paraffin, where they were dehydrated in increasing series of alcohol and diaphanized in xylol. The histological paraffin embedding was performed, longitudinally sectioned in 7  $\mu\text{m}$  thickness in a microtome (Olympus CUT 4055) and stained with hematoxylin and eosin.

The slides were photomicrographed under a light microscope (Olympus), with 200x magnification for morphology analysis. The morphological characteristics of the articular cartilage were observed, such as the distribution of chondrocytes, appearance of the articular surface and the presence of cracks in the extracellular matrix, flocculation and cellular clones, as well as the subchondral bone and the synovial membrane, and the tissue aspects of the intima and subintima were observed.

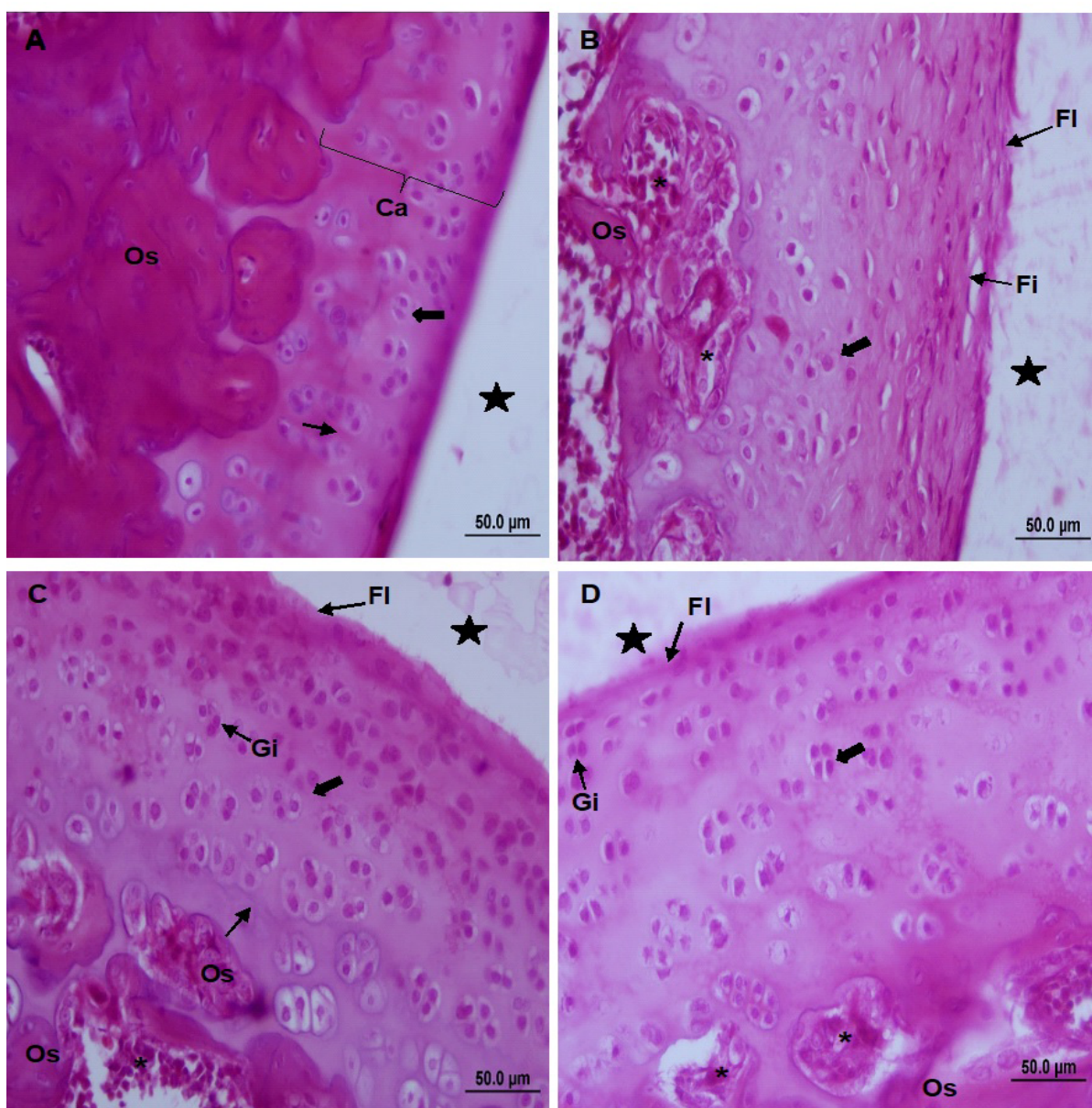
## Results

Morphological analysis of the synovial membrane of the control group (G1) revealed normal characteristics, that is, from two to three layers of synoviocytes (types A and B) in the intima synovialis, and subintima with a predominance of adipose cells and blood vessels within the normal range (Figure 1A). In the immobilized group (G2), the synovial membrane presented altered, with thickened and disorganized intima as to the distribution of the synoviocytes and subintima with substitution of adipocytes by connective tissue rich in collagen fibers, inflammatory infiltration and intense

angiogenesis, with an increase in the number and caliber of blood vessels (Figure 1B). In the animals of the free remobilization group (G3) (Fig. 1C) and trained with WBV (G4) (Figure 1D) the morphological aspects were similar to the control (G1), with the intima organized in its characteristic layers, while the subintima presented tissue reorganization, with a small amount of connective tissue and inflammatory cells and vascularization within the normal range, when compared to G2, but with inflammatory infiltrate in the joint cavity in G3 (Fig. 1C) and larger amount of adipocytes in the subintima in G4 (Fig. 1D).



**Fig. 1.** Photomicrographs of the synovial membrane of the knee joint of Wistar rats, sagittal section, staining in hematoxylin and eosin. In A, control group (G1), with thin synovial intima (black arrow) and subintima (S), with predominance of adipose cells (Ad) and blood vessels within normal range (thin arrow). In B, immobilization group (G2), thick synovial intima and disorganization of synoviocytes, in subintima replacement of fat tissue by connective rich in collagen fibers (white arrow), presence of intense inflammatory infiltrate (▼) and large amount of blood vessels. In C, free remobilization group (G3) and D, WBV group (G4), intima and subintima returning to reorganization, with presence of inflammatory cells in the joint cavity of G3. Joint cavity (star)



**Fig. 2.** Photomicrographs of femoral joint cartilage in the patellofemoral joint of Wistar rats, sagittal section, staining in hematoxylin and eosin. In A, control group (G1), normal joint cartilage organization (Ca), smooth surface, chondrocytes distributed in the characteristic zones (Black arrow), presence of tidemark (thin arrow), normal looking subchondral bone (OS) In B, immobilization group (G2), flocculations (FI) on the surface of the cartilage, fissure (Fi) in the extracellular matrix, increase in the number of chondrocytes and disorganization of the zones, invaginations in the subchondral bone with presence of vascular connective tissue (asterisk) and absence of tidemark. In C, free remobilization group (G3) and D, platform remobilization group (G4), surface flocculation, with large number of isogenic groups (Gi) in the various layers, vascular connective tissue. Joint cavity (star)

In the morphological analysis of the knee joint, the cartilage of the femur and tibia, in G1, showed normal characteristics, where the surface was smooth and the chondrocytes organized in the four cell layers, and in the surface area, they were in horizontal clusters with a flattened appearance, in the intermediate more rounded, being isolated or in isogenic groups, in the deepest organized in gaps, being separated from the calcified area by a basophilic line, tidemark. Deep in the calcified zone, the subchondral bone had a normal aspect (Fig. 2A).

In G2, it was found that immobilization caused severe morphological changes, such as disorganization and flocculations on the joint cartilage surface, cracks in the extracellular matrix, increase in the number of chondrocytes that, lost the pattern of organization in areas with increased total thickness of the joint cartilage, absence of tidemark, besides invaginations in the subchondral bone with the presence of vascular connective tissue filling the medullar space immediately adjacent to the cartilage, where vascular tunnels appeared and pen-

etrated inside the deep layer of the cartilage, destroying the subchondral plateau. These findings were most evident in the femur in the patellofemoral joint region (Fig. 2B).

In animals of groups G3 (freely remobilized) and G4 (remobilized by WBV), the morphological results were similar. The cartilage still showed flocculation, but absence of fissures in the extracellular matrix, being possible to observe the presence of groups of cellular clones or isogenic groups in the superficial layer in great quantity, with beginning of the organization of the cellular zones and beginning of tidemark organization in some points. In the subchondral bone remained areas of invagination, but with a decrease in the vascular connective tissue that filled the medullary space (Fig. 2C and 2D).

## Discussion

Morphological observations of the knee joint in the control group showed normality in the cellular organization of the synovial membrane and joint cartilage, expected in synovial joints.<sup>20,21</sup> On the other hand, the groups submitted to experimental immobilization (G2) presented morphological alterations of tissue disorganization in the synovial membrane and articular cartilage, corroborating with the findings of Kunz et al., or the free remobilization (G3) and WBV (G4) groups, there was absence of cracks in the extracellular matrix, presence of cellular clone and organization principle of the zones and tidemark, not differing between the forms of remobilization.<sup>10</sup>

Regarding the thickening of the synovial membrane, Del Carlo et al., found that immobilization degenerates the synoviotics, affecting the production of synovial fluid and the nutritional supply of the cartilage, making it rigid and causing its thickening, which is in line with what was observed in the present study, since the synovial membrane of the immobilization group (G2) proved to be totally disorganized in terms of its tissue structure, as well as the articular cartilage.<sup>22</sup>

The synovial membrane of G3 and G4 animals presented repair characteristics, with reorganization of the synoviotic layers in the intima and subintima, reduction of fibrous tissue, reappearance of adipocytes and reduction of angiogenesis. Besides these changes, a decrease in the amount of inflammatory infiltrate in the articular cavity of the remobilization group with vibratory platform was noted, while in the free remobilization group its presence was more expressive. These results corroborate the study by Vieira et al.<sup>23</sup>, in which the animals performed an exercise protocol with ladder climbing, and also showed positive results in the acceleration of tissue regeneration, however, there was no presence of inflammatory infiltrate found in the joint cavity as was seen in this study. The inflammatory res-

ponse that occurs in the synovial joints has principle in the production of interleukin-1 and tumor necrosis factor  $\alpha$  (TNF- $\alpha$ ), causing the inhibition of the production of collagen type II and proteoglycans and the stimulation of the synthesis of metalloproteinases, which act on the degradation of articular cartilage.<sup>24</sup>

In this study it was possible to verify that the immobilization protocol, for a time of 2 weeks, caused flocculations on the surface of the joint cartilage and disarrangements in the cartilaginous matrix, as already presented in the literature.<sup>10,21</sup> Synovial fluid diffusion in the articular cavity may be compromised by the immobilization procedure, hindering fluid diffusion and reducing nutrient supply to chondrocytes, leading to a reduction of its extracellular matrix and proteoglycan synthesis due to disuse.<sup>5,20,22</sup>

Del Carlo et al. found that cartilage lesions can be reversible with the use of remobilization programs.<sup>22</sup> In this study, the groups submitted to free remobilization and by WBV presented similar characteristics of tissue recovery, being observed the increased presence of isogenic groups that according to Melo et al., represent the hyperactivity of chondrocytes as an attempt of tissue repair after a period of immobilization.<sup>25</sup> Also, according to Ando et al. when a joint is submitted to its movement again, there will be a reduction in stiffness and an improvement in the synovial fluid flow in the joint cavity, thus promoting cartilage nutrition and consequent regeneration, which goes against the changes found in experimental groups submitted to free remobilization and IVC (G3 and G4).<sup>26</sup>

The use of WBV as a therapeutic method for the treatment of osteoporosis has been widely studied because of its mechanical stimulation mechanism characterized by active oscillations in bone tissue cells, as well as in muscle tissue, showing increased strength, balance, decreased risk of falls and morbidity, however there are still few studies that report its effects on joint tissues.<sup>27-32</sup> Van Heuvelen et al. point to the importance of presenting the parameters for use of the WBV, since only in this way is there a possibility of reproducibility of the results.<sup>33</sup> In this study, the WBV was used with a frequency of 60 Hz and vibrations with an amplitude of 2 millimeters, for 10 minutes, resulting in a recovery in the changes caused by the immobilization procedure similar to those found with free remobilization, with a decrease in connective tissue and inflammatory infiltration of the articular cavity in the platform group. Conversely, Mierzwa et al. observed the joint degradation of the distal part of the femurs, infringed by the use of IVC, with a frequency of 60 Hz and amplitude of 0.6 mm, for 20 minutes, 5 days a week, with total duration of 3 months.<sup>34</sup> In Wistar ovariectomized rats, it may be inferred that the difference in the choice of vibration amplitude and the time of application of the experimental model,

in the case of hormonal deprivation, may have caused the divergences in the results found with this study, and no degenerative effect was observed in the animals treated with the platform, but a subtle improvement in the inflammatory process. Seeing studies that point to a reduction in the level of pain with the use of WBV, and being that this is a basis for neurogenic inflammation, it can be inferred as one of the means by which there was the tissue alteration found.<sup>35,36</sup>

Qin et al., and McCann et al., submitted rats and mice, respectively, to experimental procedures of osteoarthritis, using WBV at lower frequencies of 35 Hz with a wave amplitude of 0.3 millimeters, for 20 minutes, for 5 days a week, with total duration of 6, 12 and 18 weeks according to the groups, while in McCann's study the frequency used was 45 Hz, with a wave amplitude of 0.3 millimeters, for 30 minutes a day, for 5 days a week, with a total duration of 4 and 8 weeks and 4 weeks with another 4 weeks of recovery according to the group, obtaining in both studies the degradation of cartilage as a tissue response.<sup>37,38</sup>

In the present study, the tissue reorganization in the subintima and the decrease of inflammatory infiltrate in the articular cavity and the presence of cellular clones of the group treated with platform vibration, showed an initiation of more effective tissue recovery response in the platform group when compared to the free. Thus, it can be inferred that the application of the platform with other treatment parameters, could accelerate the recovery process, thus, new comparative research is needed regarding the increase in treatment time and the diversification of vibratory parameters to be used.

## Conclusion

Use of WBV as a therapeutic method for remobilization, in the parameters used, showed better results in the tissue recovery of the synovial membrane of the knee joint of Wistar rats.

## Declarations

### Funding

This research received no external funding.

### Author contributions

Conceptualization, J.C.R.G., G.R.F.B., R.M.C. and L.F.C.R.; Methodology, J.C.R.G., G.R.F.B., R.M.C. and L.F.C.R.; Formal Analysis, J.C.R.G., G.R.F.B., R.M.C. and L.F.C.R.; Investigation, J.C.R.G., A.L.F.T., M.L.S.W., C.D.T.B. and D.F.S.R.; Resources, J.C.R.G., G.R.F.B., R.M.C. and L.F.C.R.; Writing – Original Draft Preparation, J.C.R.G.; Writing – Review & Editing, A.L.F.T., G.R.F.B., M.L.S.W., C.D.T.B., D.F.S.R., R.M.C. and L.F.C.R.; Visualization, J.C.R.G., A.L.F.T., G.R.F.B., M.L.S.W., C.D.T.B., D.F.S.R., R.M.C. and L.F.C.R.; Supervision, G.R.F.B., R.M.C. and L.F.C.R.; Project Ad-

ministration, G.R.F.B., R.M.C. and L.F.C.R.; Funding Acquisition, J.C.R.G., G.R.F.B., R.M.C. and L.F.C.R.

### Conflicts of interest

All authors declare that they have no conflicts of interest.

### Data availability

The data have not been made public, but are kept with the authors, if necessary.

### Ethics approval

Study was approved by the Unioeste Animal Use Ethics Committee (2729/2014-GRE).

## References

1. Andia I, Maffulli N. New biotechnologies for musculoskeletal injuries. *Surgeon*. 2019;17(4):244-255. doi:10.1016/j.surge.2018.08.004
2. Bączkiewicz D, Skiba G, Falkowski K, Domaszewski P, Selkow N. Effects of immobilization and re-mobilization on knee joint arthrokinematic motion quality. *J Clin Med*. 2020;9(2):451. doi:10.3390/jcm9020451
3. Wahl EP, Richard MJ. Management of metacarpal and phalangeal fractures in the athlete. *Clin Sports Med*. 2020;39(2):401-422. doi:10.1016/j.csm.2019.12.002
4. Tomori Y, Nanno M, Takai S. Outcomes of nonsurgical treatment for transcondylar humeral fractures in adults: Clinical results of nonoperative management. *Medicine (Baltimore)*. 2019;98(46):e17973. doi:10.1097/MD.00000000000017973
5. Vanwanseele B, Lucchinetti E, Stüssi E. The effects of immobilization on the characteristics of articular cartilage: current concepts and future directions. *Osteoarthr Cartil*. 2002;10(5):408-419. doi:10.1053/joca.2002.0529
6. Nomura M, Sakitani N, Iwasawa H, et al. Thinning of articular cartilage after joint unloading or immobilization. An experimental investigation of the pathogenesis in mice. *Osteoarthr Cartil*. 2017;25(5):727-736. doi:10.1016/j.joca.2016.11.013
7. Lu W, Wang L, Yao J, Wo C, Chen Y. C5a aggravates dysfunction of the articular cartilage and synovial fluid in rats with knee joint immobilization. *Mol Med Rep*. 2018;18(2):2110-2116. doi:10.3892/mmr.2018.9208
8. Leroux MAM, Cheung HSH, Bau JL, Wang JY, Howell DSD, Setton LA LA. Altered mechanics and histomorphometry of canine tibial cartilage following joint immobilization. *Osteoarthr Cartil*. 2001;9(7):633-640. doi:10.1053/joca.2001.0432
9. Narmoneva DA, Cheung HS, Wang JY, Howell DS, Setton LA. Altered swelling behavior of femoral cartilage following joint immobilization in a canine model. *J Orthop Res*. 2002;20(1):83-91. doi:10.1016/S0736-0266(01)00076-6
10. Kunz RI, Silva LI, Costa JRG da, et al. Alterações histomorfométricas na articulação do joelho de ra-

- tos Wistar após remobilização em meio aquático. *Fisioter e Pesqui.* 2015;22(3):317-324. doi:10.590/1809-2950/14234922032015
11. Morimoto A, Winaga H, Sakurai H, et al. Treadmill running and static stretching improve long-lasting hyperalgesia, joint limitation, and muscle atrophy induced by cast immobilization in rats. *Neurosci Lett.* 2013;534(1):295-300. doi:10.1016/j.neulet.2012.11.009
  12. Ju Y-I, Sone T, Okamoto T, Fukunaga M. Jump exercise during remobilization restores integrity of the trabecular architecture after tail suspension in young rats. *J Appl Physiol.* 2008;104(6):1594-1600. doi:10.1152/jappphysiol.01004.2007
  13. Luo X, Zhang J, Zhang C, He C, Wang P. The effect of whole-body vibration therapy on bone metabolism, motor function, and anthropometric parameters in women with postmenopausal osteoporosis. *Disabil Rehabil.* 2017;39(22):2315-2323. doi:10.1080/09638288.2016.1226417
  14. Christiansen BA, Silva MJ. The effect of varying magnitudes of whole-body vibration on several skeletal sites in mice. *Ann Biomed Eng.* 2006;34(7):1149-1156. doi:10.1007/s10439-006-9133-5
  15. Marín-Cascales E, Alcaraz PE, Ramos-Campo DJ, Martínez-Rodríguez A, Chung LH, Rubio-Arias JÁ. Whole-body vibration training and bone health in postmenopausal women: A systematic review and meta-analysis. *Medicine (Baltimore).* 2018;97(34):e11918. doi:10.1097/MD.00000000000011918
  16. Lin CI, Huang WC, Chen WC, et al. Effect of whole-body vibration training on body composition, exercise performance and biochemical responses in middle-aged mice. *Metabolism.* 2015;64(9):1146-1156. doi:10.1016/j.metabol.2015.05.007
  17. Wang L, Wang Z, Liu Q, Su J, Wang T, Li T. Effect of whole body vibration on HIF-2 $\alpha$  expression in SD rats with early knee osteoarthritis. *J Bone Miner Metab.* Published online 2020:Epub ahead of print. doi:10.1007/s00774-020-01092-3
  18. Zazula MF, Wutzke MLS, da Costa JRG, et al. Morphological effects of whole-body vibration on remobilization of the tibialis anterior muscle of Wistar rats. *Anat Rec.* 2020;303(11):2857-2864. doi:10.1002/ar.24390
  19. Kakhata CMM, Peretti AL, Wutzke MLS, et al. Morphological and nociceptive effects of mechanical vibration on the sciatic nerve of oophorectomized Wistar rats. *Motriz.* 2019;25(1):e101949. doi:10.1590/s1980-6574201900010005
  20. Kojima S, Hosono M, Watanabe M, Matsuzaki T, Hibino I, Sasaki K. Experimental joint immobilization and remobilization in the rats. *J Phys Ther Sci.* 2014;26(6):865-871. doi:10.1589/jpts.26.865
  21. Nagai M, Aoyama T, Ito A, et al. Alteration of cartilage surface collagen fibers differs locally after immobilization of knee joints in rats. *J Anat.* 2015;226(5):447-457. doi:10.1111/joa.12290
  22. Del Carlo RJ, Galvão MR, Vitoria MI V, et al. Imobilização prolongada e remobilização da articulação fêmoro-tíbio-patelar de ratos: estudo clínico e microscópico. *Arq Bras Med Vetrinária e Zootec.* 2007;59(2):363-370.
  23. Vieira L, Lovison K, Kunz RI, et al. Resistance exercise recovers the structure of cartilage and synovial membrane of the ankle joint of rats after sciatic compression. *Mot Rev Educ Física.* 2017;23(3):e101707. doi:10.1590/s1980-6574201700030001
  24. Elsaid KA, Jay GD, Chichester CO. Reduced expression and proteolytic susceptibility of lubricin/superficial zone protein may explain early elevation in the coefficient of friction in the joints of rats with antigen-induced arthritis. *Arthritis Rheum.* 2007;56(1):108-116. doi:10.1002/art.22321
  25. Melo EG, Nunes VA, Rezende CMF, Gomes MG, Malm C, Gheller VA. Sulfato de condroitina e hialuronato de sódio no tratamento da doença articular degenerativa em cães. Estudo histológico da cartilagem articular e membrana sinovial. *Arq Bras Med Vet e Zootec.* 2008;60(1):83-92. doi:10.1590/S0102-09352008000100013
  26. Ando A, Hagiwara Y, Chimoto E, Hatori K, Onoda Y, Itoi E. Intra-articular injection of hyaluronan diminishes loss of chondrocytes in a rat immobilized-knee model. *Tohoku J Exp Med.* 2008;215(4):321-331. doi:10.1620/tjem.215.321
  27. Weber-Rajek M, Mieszkowski J, Niespodziński B, Ciechanowska K. Whole-body vibration exercise in postmenopausal osteoporosis. *Prz Menopauzalny.* 2015;14(1):41-47. doi:10.5114/pm.2015.48679
  28. Gnyubkin V, Guignandon A, Laroche N, Vanden-Bossche A, Malaval L, Vico L. High-acceleration whole body vibration stimulates cortical bone accrual and increases bone mineral content in growing mice. *J Biomech.* 2016;49(9):1899-1908. doi:10.1016/j.jbiomech.2016.04.031
  29. Xu J, Lombardi G, Jiao W, Banfi G. Effects of exercise on bone status in female subjects, from young girls to postmenopausal women: an overview of systematic reviews and meta-analyses. *Sport Med.* 2016;46(8):1165-1182. doi:10.1007/s40279-016-0494-0
  30. Park S-Y, Son W-M, Kwon O-S. Effects of whole body vibration training on body composition, skeletal muscle strength, and cardiovascular health. *J Exerc Rehabil.* 2015;11(6):289-295. doi:10.12965/jer.150254
  31. Bembem D, Stark C, Taiar R, Bernardo-Filho M. Relevance of whole-body vibration exercises on muscle strength/power and bone of elderly individuals. *Dose-Response.* 2018;16(4):155932581881306. doi:10.1177/1559325818813066
  32. Sá-Caputo D, Paineiras-Domingos LL, Francisca-Santos A, et al. Whole-body vibration improves the functional parameters of individuals with metabolic syndrome: An exploratory study. *BMC Endocr Disord.* 2019;19(1):6. doi:10.1186/s12902-018-0329-0
  33. Van Heuvelen MJG, Rittweger J, Judex S, et al. Reporting guidelines for whole-body vibration studies in hu-

- mans, animals and cell cultures: A consensus statement from an international group of experts. *Biology (Basel)*. 2021;10:965. doi:10.3390/biology10100965
34. Mierzwa AGH, Campos JF, Jesus MF, Nader HB, Lazaretti-Castro M, Reginato RD. Different doses of strontium ranelate and mechanical vibration modulate distinct responses in the articular cartilage of ovariectomized rats. *Osteoarthr Cartil*. 2017;25(7):1179-1188. doi:10.1016/j.joca.2017.02.793
35. Sá-Caputo DC, Paineiras-Domingos LL, Oliveira R, et al. Acute effects of whole-body vibration on the pain level, flexibility, and cardiovascular responses in individuals with metabolic syndrome. *Dose-Response*. 2018;16(4):1-9. doi:10.1177/1559325818802139
36. Kelly S, Dunham JP, Donaldson LF. Sensory nerves have altered function contralateral to a monoarthritis and may contribute to the symmetrical spread of inflammation. *Eur J Neurosci*. 2007;26(4):935-942. doi:10.1111/j.1460-9568.2007.05737.x
37. Qin J, Chow SKH, Guo A, Wong WN, Leung KS, Cheung WH. Low magnitude high frequency vibration accelerated cartilage degeneration but improved epiphyseal bone formation in anterior cruciate ligament transect induced osteoarthritis rat model. *Osteoarthr Cartil*. 2014;22(7):1061-1067. doi:10.1016/j.joca.2014.05.004
38. McCann MR, Yeung C, Pest MA, et al. Whole-body vibration of mice induces articular cartilage degeneration with minimal changes in subchondral bone. *Osteoarthr Cartil*. 2017;25(5):770-778. doi:10.1016/j.joca.2016.11.001