



CASUISTIC PAPER

Krzysztof Milik ^{1(ABCDEF)}, Grzegorz Pasternak ^{2(ABCDEF)}, David Aebisher  ^{2(EF)}

Brachial artery injury

¹ Department of Vascular Surgery, District Hospital, Mielec, Poland

² Medical College of Rzeszów University, Rzeszów, Poland

ABSTRACT

Introduction. Arterial damage associated with musculoskeletal injuries at room conditions is very common.

Aim. It is worth remembering that examining a patient who has suffered an accident with a broken bone or traumatic joint dislocation may be accompanied by vascular damage. A dislocation or fracture often masks damage to the artery.

Description of the case. In this paper, a 20-year-old patient being a passenger suffered upper right limb trauma in a car accident.

Conclusion. The effects of vascular injuries appear only after a few hours after setting the fracture. It is not known then whether the artery was damaged at the same time with the fracture, whether the injury occurred during the adjustment, or whether the ischemia is finally the result of the pressure exerted by too tight plaster casts.

Keywords. broken bone, traumatic joint dislocation, vascular injuries

Introduction

Penetrating injuries, i.e. open ones, are much more common than closed ones and they are divided into: lateral wounds, transverse cuts and rupture of the artery. Gunshot wounds require additional discussion. Lateral wounds account for 60% of arterial injuries observed during the peace period. In the case of lateral injuries, which are the most common in peacetime, a significant vasoconstriction occurs, causing the bleeding to increase. In a cut artery, most often with a knife, the edges of the wound are even and shrinkage of the artery results in a decrease. The artery rupture occurs as a result of extensive open injuries (e.g. traffic, industrial accidents). The edges of the wound are jagged, the inner membrane curls inwards, which promotes thrombus forma-

tion. Vessel bleeding stops. It should be remembered that thrombi periodically stopping bleeding, after withdrawal of the spasm and resolution of the shock, may be squeezed out of the lumen of the artery, resulting in secondary bleeding. Gunshot wounds are characterized by numerous changes in the areas of the primary projectile channel, which is associated with high kinetic energy of the projectile. There are considerable pressure fluctuations in this channel, which can lead to cracks and detachment of the intimal membranes often far away from the bullet path. Blunt injuries, i.e. closed arteries, are divided into bruises, dissections, adventitious cracks and spasm of the vessels.¹⁻⁴ They are a consequence of blunt direct and indirect injuries and are characterized by the absence of coating wounds. Symptoms of vascular dam-

Corresponding author: Grzegorz Pasternak, e-mail: g.past@op.pl

Participation of co-authors: A – Author of the concept and objectives of paper; B – collection of data; C – implementation of research; D – elaborate, analysis and interpretation of data; E – statistical analysis; F – preparation of a manuscript; G – working out the literature; H – obtaining funds

Received: 5.04.2020 | Accepted: 12.05.2020

Publication date: June 2020

age can be divided into “large” and “small” (“hard” and “soft” signs) Symptoms of “large” are bleeding, massive hematoma, features of peripheral ischemia of the limb - coldness of the limb, no sensation, no pulse distal to the site of injury.¹⁻⁴ All these symptoms can occur at very low intensity or, as in the absence of a pulse on the perimeter, do not occur. We then talk about the symptoms of so-called “Small”, i.e. heart deficit without limb ischemia, local hematoma and neurological disorders associated with other injuries, e.g. bone fractures. Shrinking of the ends of the vessel, the formation of thrombi may result in slight bleeding from the vessel. Good collateral circulation can compensate for the lack of blood flow through the axial vessels, which results in resting limb with weakly discernible symptoms or lack of ischemic features. Also, collateral circulation in some arteries may be responsible for the presence of a pulse around the perimeter, of course with slightly less filling.¹⁻⁴

Aim

The paper presents the diagnosis with the subjective and physical examination.

Description of the case

A 20-year-old patient being a passenger suffered upper right limb trauma in a car accident. The orthopedist found a posterior dislocation of the right elbow with avulsive injury to the anterior elbow bag. He repositioned a dislocation under general anesthesia. However, he also noticed symptoms of acute right upper limb ischemia. Urgent vascular surgeon was asked to consult. Acute post-traumatic ischemia of the right upper limb was confirmed suspecting the right brachial artery injury by double imaging. After taking tests and securing blood for a patient qualified for urgent surgery (Figure 1). A transverse incision in the elbow with a proximal extension on the frame after the evacuation of the hematoma was found to tear the brachial artery with a distal adnexal fracture of the distal and proximal part and with a defect of about 10 cm artery. Extensive damage to the brachial veins at the site of injury was also found, which was ligated. Due to extensive damage to the elbow and muscles, orthopedic intervention was requested. The primary repair was the avulsive injury of the right elbow anterior bag. An elbow sac cap with a Wedge Anchor titanium anchor with Force fiber sutures was also sewn in. The collateral ligaments were left for secondary reconstruction. After dissection and refreshing of the brachial artery margins, arterial segments with subadventitious rupture were removed (Figure 2). Thrombectomy of the Fogarty catheter in the distal and proximal brachial artery was performed, resulting in good outflow and inflow of the brachial artery. The ulnar vein was removed and a number of anastomoses of the superficial veins in the elbow had been found, which

should ensure sufficient blood outflow from the arm. However, with elbow flexion movements, a haemodynamically significant drop in arterial flow was found in intraoperative Doppler ultrasound. Brachial artery ends were dissected and freed again. The span was shortened and slightly displaced, which resulted in better flow after bending the right elbow. Doppler ultrasound examination showed two-phase and high resistance flow.

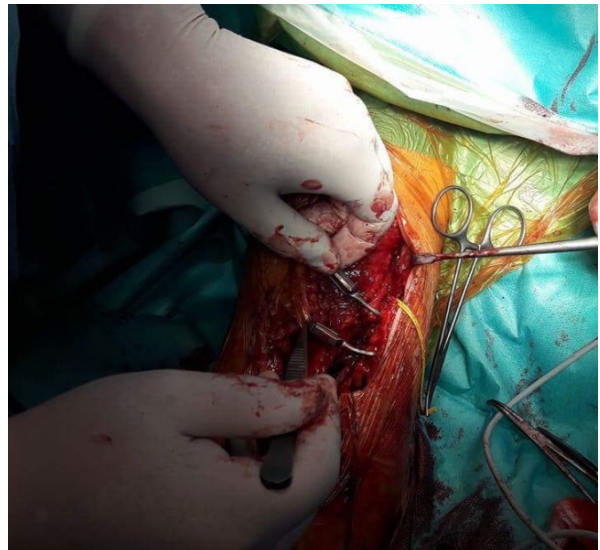


Fig. 1. Rupture of the brachial artery with visible defect despite dissection and activation of the vessel ends

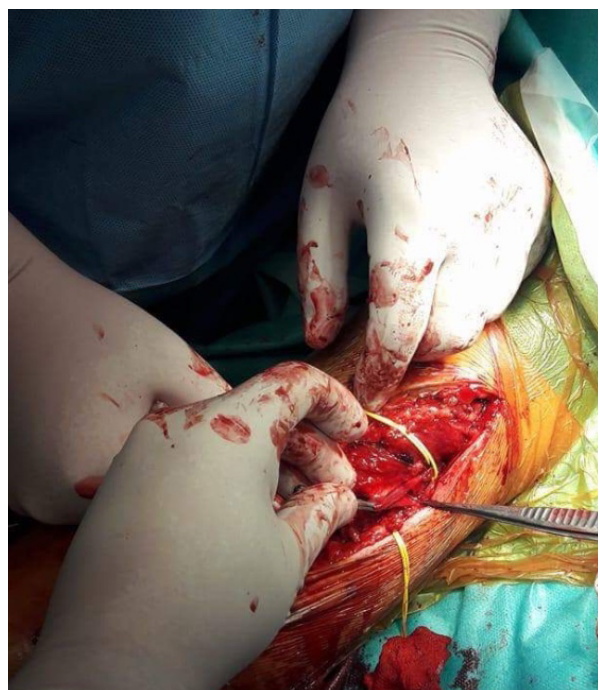

Fig. 2. Just before removing the vascular clamp to activate flow through the brachial bridge

The course of postoperative treatment without major complications. At first, the patient felt only numbness of the fingers and slight swelling of the forearm.

Warming and blood supply to the right upper limb normal. The pulse was well felt on the radial and ulnar arteries. Active finger movements and sensation preserved. The patient had a fixation brace on. The patient was discharged with the wound during normal healing. The patient reported for control- 7 days, 1 month, 3 months, 6 months after discharge from the hospital. The patient had sutures removed on the 12th day after surgery, the splint was removed a month after leaving the hospital. During follow-up examinations, the blood supply did not deteriorate, the feeling of numbness in the fingers of the right hand subsided. Contracture in the elbow and the weakness of the right arm muscle lasted for a long time. However, thanks to the implemented rehabilitation, the range of motion in the elbow and the degree of muscle strength improved significantly. Fore-arm swelling persisted for up to 3 months after the procedure, then gradually subsided. The patient currently leads a normal life using the upper right limb to the full extent without any restrictions (Figure 3).

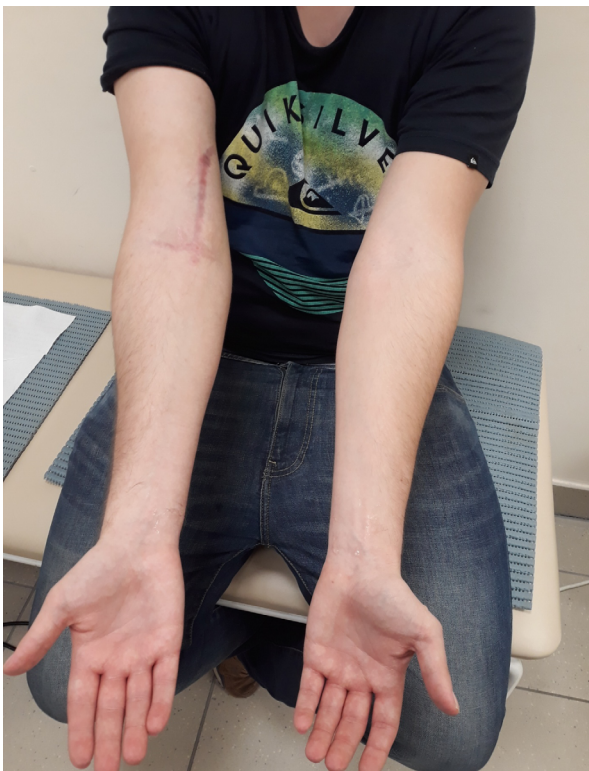

Fig. 3. Condition after last control visit

Discussion

Physical examination should be supported by ultrasound examination, oximetry or ABPI index testing. Currently, the best diagnostic tool is computed tomography with a contrast agent. Angiography is used to recognize trauma to smaller axial vessels located peripherally. However, the need for a delay in the event of an urgent surgery limits its use, above all to diagnostically difficult cases. There are often indications for arte-

riography during surgery.⁵ First aid at the accident site is to control bleeding. This can be achieved by compressing the artery at the wound site and applying a pressure dressing. However, if limb bleeding persists, the cuff of the blood pressure monitor should be applied cardially from injury, pumping it to the appropriate level (200-250 mm Hg). Hemorrhage may lead to hypovolemic shock. It is important to implement the anti-shock procedure as early as possible. Access to the vein should be ensured, transfusions of blood replacers should be started, painkillers should be used, the patient should be positioned comfortably and the cover should be warm. A patient with probable vascular injury, in hypotension, with a systolic pressure <90 mmHg should be through a traumatic syndrome. The team should include: surgeon, interventional radiologist, orthopedic traumatologist, neurosurgeon and anesthesiologist. The patient should be provided with immediate access to the T-examination and operating room. For patients unstable in hypovolemic shock, one of the basic tools for ensuring circulatory stability is a resuscitative endovascular balloon occlusion of the aorta (REBOA), especially applicable to patients with chest and abdominal injuries. Antibiotic prophylaxis should always be considered before surgery and administration after surgery. Usually, classic methods of vessel reconstruction are used: primary suture, primary suture with venous or artificial patches, use of endogenous vein prostheses, artificial PTFE (Gore-Tex), Dacron. In exceptional circumstances - severe condition of the patient and with good collateral circulation, axial vessel ligation is possible. Recently, thanks to advances in endovascular surgery, stable patients can be treated using this surgical technique. It is often enough to close the small branches of the iliac arteries with the help of embolising materials: gelatin sponges, coil springs or surgical glues. Some arterial injuries can be treated by expanding the lumen of an endovascular prosthesis. In the case of dissections, the main goal is to supply the dissection gates, create conditions for clotting the false channel and directing blood to the proper channel. It seems that bare metal stents (BMS) and cobalt-chrome ones are best suited for this. Vessels exposed to external pressure are supplied with the help of nitinol self-expanding stents. Balloon expansion stents should be used in the initial sections of large vessels, where the accuracy of stent implantation is particularly important. Stent grafts are used in patients with interrupted arterial wall with possible passage through the guide wire in the lumen of the vessel. Stent grafts have also been used in the treatment of pseudo-aneurysms and post-traumatic arteriovenous fistulas.²⁻⁶ With simultaneous artery damage and long bone fracture, management depends on the severity of ischemia. In case of severe limb ischemia, it may be necessary to undergo repair surgery before setting the bone

fracture. If the ischemia is minor, the fracture should be set first. In cases of multiple fractures, external stabilization seems to be the best solution. If the orthopedic surgery is prolonged and the blood supply to the limb worsens then a good solution is to place a temporary internal flow (shuntu) in the wounded artery.⁷ The brachial artery is the most frequently damaged vessel in both peaceful and war conditions. It can be damaged if the shoulder and elbow are dislocated. Often, the brachial artery injury can be overlooked because the brachial plexus or its branch is damaged at the same time and then the symptoms of nerve damage are dominant. Good collateral circulation means that even a complete closure of the brachial artery may not lead to acute ischemia of the hand. Only the accumulation of blood under the fascia leads to the formation of the compartment syndrome (compartment syndrome), which results in ischemia and Volkmann's contracture. In order to treat the brachial artery injury, the arteries are usually exposed through a cut along the medial edge of the biceps or in the elbow pit. Remember not to damage the median nerve. The brachial artery after starting the stumps usually manages to end-to-end anastomosis, but sometimes it may be necessary to use a bridge. If the damage is widespread, blood flow should be brought even to the point of departure of the deep arm artery. Often, despite the restoration of circulation, simultaneous damage to the brachial plexus and shoulder-clavicular joint can cause a significant reduction in limb efficiency. With a large swelling of the forearm after surgery and the possibility of Volkman's contracture, the forearm fasciotomy must be remembered.⁴⁻⁹ The surgeon's cooperation with the anesthesiologist is very important. The type of anesthesia affects the patient's condition and the operator's comfort of work. We have the option of general, local or local anesthesia. It seems that the type of anesthesia determines the type and severity of the injury itself and the general condition of the patient. While the patient's condition is good, i.e. it does not have general loads such as circulatory or renal failure, advanced respiratory failure and is not in shock, general anesthesia is the best type of anesthesia for extensive brachial artery injury. Local anesthesia is reserved for minor damage to the artery and the patient is in poor condition. Conduction anesthesia is possible provided no damage to the shoulder plexus has occurred. It is also important for the anaesthesiologist to take care of the patient's stable condition throughout the period of anesthesia and surgery, and in the postoperative period. Monitoring of pulse pressure, diuresis, fluid balance is one of the basic activities that must be performed in the intensive supervision room, where the patient should be found after the surgery.¹⁰⁻¹⁶ It is also advisable to work closely with a neurologist to detect peripheral nerve damage early and respond appropriately to existing problems. In

the case of bone or joint damage, an orthopedic surgeon will play an important role in the treatment process, as well as in a rehabilitator focused on starting the damaged limb as soon as possible.

Conclusion

Based on the above data, it should be concluded that in the case of extensive damage to vessels complicated by damage to bone, muscle and nerve structures, a syndrome is needed highly specialized professionals to obtain a beneficial effect of treatment. Often, however, typical symptoms can be masked by damage to other organs and the extent of the damage.

References

- Ornekhan V, Sava J, Malik RK. From trauma to treatment: optimizing vascular trauma patient management. *Endovasc Today*. 2016;1:56-55.
- Yamada R, Guimares M, Schoenholz C. Vascular Trauma: Be ready for anything. *Endovasc Today*. 2016;1:50-55.
- Rasmussen TE, Sampson JB, Cannon JW, Darrin Clouse W. Endovascular capability for wartime injury. *Endovasc Today*. 2016;1:67-72.
- Rajeev A, Timmons G. Axillary Artery Injury with Intact Radial Pulse following Fracture-Dislocation of Shoulder: A Case Report. *Malays Orthop J*. 2019;13(3):66-68.
- Berroug J, Korcarz CE, Mitchell CK, et al. Brachial artery intima-media thickness and grayscale texture changes in patients with peripheral artery disease receiving supervised exercise training in the PROPEL randomized clinical trial. *Vasc Med*. 2019;24(1):12-22.
- Masionis P, Bobina R, Uvarovas V, Porvaneckas N, Šatkauskas I. Thrombosis of the brachial artery - a rare and devastating complication after a simple closed posterolateral elbow dislocation. *Acta Med Litu*. 2019;26(3):167-172.
- Konschake M, Stofferin H, Moriggl B. Ultrasound visualization of an underestimated structure: the bicipital aponeurosis. *Surg Radiol Anat*. 2017;39(12):1317-1322.
- Strong DP, Edwards AT. Vascular trauma. *Trauma*. 2002;4(1):39-42.
- Yichi X Wenjing X, Aiyuan W, et al. Diagnosis and treatment of traumatic vascular injury of limbs in military and emergency medicine. *Medicine*: 2019;98(18):e15406.
- Chuaychoosakoon C, Suwanno P, Boonriong T, et al. Patient Position Is Related to the Risk of Neurovascular Injury in Clavicular Plating: A Cadaveric Study. *Clin Orthop Relat Res*. 2019;477(12):2761-2768.
- Gilani R, Ochoa L, Wall MJ Jr, Tsai PI, Mattox KL. Endovascular repair of traumatic aortic injury using a custom fenestrated endograft to preserve the left subclavian artery. *Vasc Endovascular Surg*. 2011;45(6):549-552.
- Hosn MA, Nicholson R, Turek J, Sharp WJ, Pascarella L. Endovascular Treatment of a Traumatic Thoracic Aortic Injury in an Eight-Year Old Patient: Case Report and Review of Literature. *Ann Vasc Surg*. 2017;39:292.e1-292.e4.

13. Coccolini F, Ceresoli M, McGreevy DT, et al. Aortic balloon occlusion (REBOA) in pelvic ring injuries: preliminary results of the ABO *Trauma Registry*. *Updates Surg*. 2020, doi: 10.1007/s13304-020-00735-4.
14. Alhaizaey A, Aljabri B, Alghamdi M, et al. Delayed Aortic Stent Collapse in Blunt Traumatic Aortic Injury Repair. *Aorta (Stamford)*. 2019;7(5):129-136.
15. Chang H, Hadro NC, Norris MA, Morris ME. Endovascular Treatment of Blunt Thoracic Aortic Injuries in Right Arch Vessel Anatomy. *Ann Thorac Surg*. 2020;109(3):e225.
16. Elkbuli A, Dowd B, Spano PJ, Smith Z, Flores R, McKenney M, Boneva D. Thoracic Endovascular Aortic Repair Versus Open Repair: Analysis of the National Trauma Data Bank *J Surg Res*. 2020;245:179-182.