

# A STUDY OF OXIDATIVE STRESS AND PULMONARY DAMAGE AFTER SILICA INSTILLATION IN RATS AND THE EFFECT OF CURCUMIN ADMINISTRATION

Maria Barsan<sup>1</sup>, Armand Gabriel Rajnoveanu<sup>1</sup>, Aristotel Cocarla<sup>1</sup>, Pompei Bolfa<sup>2,3</sup>, Cezar C. Login<sup>4</sup>, Andreea Iulia Socaciu<sup>1</sup>, Nicoleta Decea<sup>4</sup>, Daniel-Corneliu Leucuta<sup>5</sup>

<sup>1</sup> Iuliu Hatieganu University of Medicine and Pharmacy, Cluj-Napoca, Romania  
Department of Occupational Medicine

<sup>2</sup> University of Agricultural Sciences and Veterinary Medicine, Cluj-Napoca, Romania  
Department of Pathology

<sup>3</sup> Ross University School of Veterinary Medicine, Basseterre, St. Kitts, West Indies  
Department of Biomedical Sciences

<sup>4</sup> Iuliu Hatieganu University of Medicine and Pharmacy, Cluj-Napoca, Romania  
Department of Physiology

<sup>5</sup> Iuliu Hatieganu University of Medicine and Pharmacy, Cluj-Napoca, Romania  
Department of Medical Informatics and Biostatistics

## ABSTRACT

**Background:** The authors' aim was to study the dynamics of oxidative stress in experimental exposure to silica dust, to evaluate the histopathological findings in the phase preceding the formation of fibrous/fibrohyaline pulmonary nodules, and to assess the effects of curcumin administration. **Material and Methods:** The research was performed on 48 male Wistar rats with an average weight of 320 g. Overall, 38 rats were instilled with a single dose of 0.3 ml suspension containing 30 mg of a SiO<sub>2</sub>/ml saline solution, and were sacrificed 30, 90 and 120 days after instillation; 14 of those sacrificed on days 90 and 120 also received curcumin. The control group included 10 animals which were instilled with a saline solution. Malondialdehyde (MDA), carbonyl proteins (CPs), total thiolic proteins (TPs) and reduced glutathione (GSH) were determined in blood and the lung tissue. The standard technique for pulmonary toxicology developed by Porter was applied to semi-quantitatively assess the histopathological findings. **Results:** It was found that MDA had increased significantly early on in both biological environments and remained elevated, and adding curcumin proved beneficial, while CPs only increased moderately in the lung tissue without a curcumin impact. Moreover, TPs dropped abruptly, significantly and persistently in the lung tissue and blood, and were not influenced by curcumin. Finally, GSH decreased significantly and intensely in the lung tissue and blood, with curcumin lowering the levels towards those found within the control group. The histopathological examination identified nodules of a cellular type, without any fibrosis, but with spots of associated lipoproteinosis. The early lesions in the airways and vessels were suggestive of a remodeling process. Curcumin diminished the occurrence of alveolitis but not the remodeling process. **Conclusions:** The study confirms the early onset of oxidative stress in experimental silicosis. It also simultaneously and dynamically researches markers of oxidative stress in blood and the lung tissue. Curcumin proved beneficial on oxidative stress and lesions in the alveolar epithelia, but ineffective in preventing vascular and airway remodeling. *Med Pr.* 2021;72(3):239–47

**Key words:** curcumin, silicosis, experimental study, silica, oxidative stress, lung tissue

Corresponding author: Armand Gabriel Rajnoveanu, Iuliu Hatieganu University of Medicine and Pharmacy, Department of Occupational Medicine, Victor Babes 8, 400012 Cluj-Napoca, Romania, e-mail: armand.rajnoveanu@umfcluj.ro  
Received: July 28, 2020, accepted: January 25, 2021

## INTRODUCTION

Oxidative stress is a disorder of balance between the production of reactive oxygen species (ROS) and the ability of the antioxidant system to neutralize them [1,2], caused either by an excessive production of ROS or by a decrease in antioxidant defensive mechanisms [3]. The presence of oxidative stress in silicosis was confirmed by numerous clinical and experimental studies [1,2,4–7]. The formation of ROS is either an effect of

the surface activity exhibited by crystalline quartz, with the intensity of the process depending upon the freshness of the fractured silica [8,9], or they are formed and released by the inflammatory cells, especially polymorphonuclear cells and activated macrophages, after the phagocytosis of the silica particles. Notably, ROS stimulate the secretion of cytokines and other mediators that promote inflammation and fibrosis.

The damage caused by interstitial fibrosis, whether alone or in combination with smoking, is responsible

for the main functional impairment found in silicosis, i.e., airway obstruction. Peripheral airway disease in subjects exposed to silica dust inhalation is present with an incomparably higher frequency, even in the absence of radiological signs for silicosis [10].

A particular interest among expansive research for alternative therapies for silicosis is focused on curcumin, a natural polyphenol product isolated from the rhizome of the *Curcuma longa*, a plant native in India and commonly known as turmeric. Several studies from the last decade have claimed curcumin to have antioxidant and anti-inflammatory effects [11–13], i.e., properties with therapeutic interest when it comes to chronic inflammatory diseases, including silicosis.

The aim of this study was to investigate the dynamics of oxidative stress, concurrent with histopathological findings in a phase prior to the formation of fibrous and fibrohyaline nodules. Within the experiment, the authors considered it to be of interest to assess the potential protective effects of curcumin against oxidative stress and its possible influence on the histopathological aspects found at the level of the lung parenchyma, mainly the peripheral airway and blood vessels.

## MATERIAL AND METHODS

The research was performed on male Wistar rats with an average weight of 320 g. Silicon dioxide (SiO<sub>2</sub>) was instilled intratracheally in a single 0.3 ml dose from a suspension containing 30 mg of a SiO<sub>2</sub>/ml saline solution after the animals were anesthetized using a mixture of Ketamine 10% and Xylazine 2% in a 2:1 ratio. The authors used the standardized crystalline SiO<sub>2</sub> MIN-U-SIL® 5 produced by Berkeley Springs, West Virginia (USA), with a spherical diameter equivalent to 1.6 μm, a purity of 99.2% and 96% of the particles with a diameter of <5 μm.

The rats were divided into 6 groups (Table 1): the control group (instilled intratracheally with 0.3 ml of the saline solution and sacrificed after 30 days); and 3 groups treated with SiO<sub>2</sub> and sacrificed after 30 days (SiO<sub>2</sub>.30), after 90 days (SiO<sub>2</sub>.90) and after 120 days (SiO<sub>2</sub>.120), respectively. The remaining 2 groups of animals treated with SiO<sub>2</sub> additionally received Sigma-Aldrich produced curcumin throughout the experiment, with end points of 90 and 120 days, respectively. Curcumin content in curcuminoid was ≥94% and in curcumin ≥80%. Curcumin was administered orally in a 50 mg/kg dose starting on day 10 after SiO<sub>2</sub> instillation, 3 doses/week. The animals were kept in the vivarium and fed

**Table 1.** The animal groups layout of the experimental study performed in the Biobase of the Department of Physiology, Iuliu Hatieganu University of Medicine and Pharmacy, Cluj-Napoca, Romania, 2012

Group	Animals [n]
Control	10
SiO <sub>2</sub> .30	9
SiO <sub>2</sub> .90	8
SiO <sub>2</sub> .90+C	7
SiO <sub>2</sub> .120	7
SiO <sub>2</sub> .120+C	7

Control – animals instilled with a saline solution, SiO<sub>2</sub>.30 – animals exposed to silica dust and sacrificed after 30 days, SiO<sub>2</sub>.90 – animals exposed to silica dust and sacrificed after 90 days, SiO<sub>2</sub>.120 – animals exposed to silica dust and sacrificed after 120 days, SiO<sub>2</sub>.90+C – animals exposed to silica dust, treated with curcumin and sacrificed after 90 days, SiO<sub>2</sub>.120+C – animals exposed to silica dust, treated with curcumin and sacrificed after 120 days.

*ad libitum*. The protocol of the experiment was approved by the University Ethics Committee (agreement No. 550A/29.02.2012). Blood samples were collected from the retro-orbital sinus in K3EDTA 3 ml vacutainers. The rats were euthanized using an overdose of an anesthetic mixture (i.e., the dose used at instillation was doubled). After the euthanasia, the authors collected trachea and lung samples for biochemical and histopathological studies. Malondialdehyde (MDA), carbonyl proteins (CPs), total thiolic proteins (TPs) and reduced glutathione (GSH) levels were determined.

In order to determine the MDA levels, the collected tissue samples were homogenized with the Polytron PT1200E homogenizer using a TRIS pH 7.5 tampon solution, and the tissue homogenate, respectively the blood, was boiled for an hour with a 2-thiobarbituric 10 mM acid solution in K<sub>2</sub>HPO<sub>4</sub> 75 mM at a pH of 3. The product of this reaction was extracted in n-butanol after suddenly cooling the sample, and the MDA concentration was determined in the organic phase after separation and centrifugation using the sincrone fluorescence technique at a 14 nm difference of wavelength (Δλ) between excitation and emission. For measuring the intensity at 534 nm of the emission, the authors used a Perkin-Elmer fluorescence spectrometer. The MDA concentration was established using a calibration curve with known concentrations of pure MDA that were processed using the same method. The obtained values were expressed in nmol/mg proteins [14].

The CPs present in blood and tissue homogenate were evaluated using the technique of determining 2,4-dinitrophenylhydrazone by fluorescence

spectrometry which, in turn, is a product of the reaction between the carbonyl compound and 2,4-dinitrophenylhydrazine. The obtained results were expressed in nmol/mg proteins [15].

The total TPs were assessed using the Ellman reagent, based upon the reaction between SH compounds and 5,5'-dithiobis-(2-nitrobenzoic acid), and the obtained results expressed in  $\mu\text{mol/ml}$  [16].

Reduced GSH was evaluated in the lung tissue and blood using the fluorescence of the product formed by the reaction between GSH and phthalic aldehyde. Readings were performed with the Perkin-Elmer fluorescence spectrometer and the results were expressed in nmol/mg proteins [16].

The protein determination was performed using the method described by Bradford [17].

For the histopathological study, the lungs were sampled using longitudinal cuts of the left lung, in the areas where maximal length sections were possible, perpendicular to the large bronchi. The fragments were fixed in a 10% formalin solution for 48 h, and then trimmed, washed, included in paraffin, sectioned, deparaffinized, and stained using hematoxylin-eosin and Masson's trichrome stains. The images were acquired and processed using an Olympus system. The veterinary pathologist applied the standard technique for pulmonary toxicology developed by Porter et al. [18] in experimental studies on silicotic fibrosis to semi quantitatively assess the histopathological findings. In each animal, the authors examined multiple sections for the histopathologic evaluation to be representative, evaluating alveolitis, alveolar epithelium changes (hypertrophy/hyperplasia) and lipoproteinosis. The alterations detected were appreciated using a severity score (0 = none, 1 = minimal, 2 = mild, 3 = moderate, 4 = marked and 5 = severe), and another score for the extension (0 = none, 1 = focal, 2 = locally extensive, 3 = multifocal and coalescent, 5 = diffuse). The lesion score per animal was calculated as the sum of scores from each examined section and, following which an average score was determined for each studied group.

The blood and parenchymal levels of the investigated markers of oxidative stress, as well as the histopathological score were statistically analyzed using MedCalc.

## RESULTS

The MDA levels rose significantly early on in lung tissue, as well as in blood, maintaining a high level throughout the experiment (Table 2). The addition of

curcumin was associated with significantly lower levels of MDA in both biological environments: the lung tissue ( $p = 0.007$ ) and blood ( $p = 0.0001$ ) on day 90. The effectiveness of curcumin was maintained on day 120 as well, with the decrease in the MDA concentration in the lung tissue being at the threshold for statistical significance ( $p = 0.06$ ), but highly significant in blood ( $p = 0.0085$ ).

Carbonyl protein levels rose moderately, but to a statistically significant degree, in lung tissue for the entire duration of the experiment, but without any concurrence in blood (Table 2). Curcumin ingestion did not influence the concentration of CPs in the lung tissue or blood, the differences in levels between the groups with protection and those without being considered insignificant on day 90 as well as on day 120.

The total TP levels dropped abruptly, significantly in the lung tissue and blood, staying low throughout the entire experiment (Table 2). Adding curcumin did not influence the TP concentration compared to the animals that did not receive curcumin protection (statistically insignificant differences).

The reduced GSH decreased significantly and intensely 30 days after silica instillation in the lung tissue as well as in blood (Table 2). Thirty days after silica instillation, the GSH content in the lung tissue was lower than that in half of the control group. The GSH decline was sustained in both biologic environments throughout the experiment and curcumin protection proved useful with normalizing effects.

No microscopic changes were observed in group 1 (control, Figure 1a). The silicotic nodules observed on day 90, but more frequently on day 120, were of a cellular type (Figure 1b), and were frequently associated with lipoproteinosis. The wall of some peribronchiolar arteries increased in size by concentric layers of hyperplastic and hypertrophied smooth muscle cells, along with increases in the matrix, resulting in a reduction of the vascular lumen (Figure 1b). The thickening of the alveolar septae with type II alveolar cell hyperplasia and intra-alveolar histiocytes, often associated with focal lipoproteinosis, was noted early on (day 30) and persisted throughout the different experimental time-points (Figure 1c). Lesions at the level of the airways and blood vessels included mild bronchiolar epithelial hyperplasia, peribronchiolar cellular infiltrates containing macrophages, lymphocytes and few neutrophils. Curcumin ingestion was associated with a mild reduction of the inflammatory cellular infiltrate intensity, with no apparent effect on

**Table 2.** The dynamics of the malonyldialdehyde (MDA), carbonyl proteins (CPs), thiolic proteins (TPs) and reduced glutathione (GSH) levels in the lung tissue and blood of animals in the experimental study performed in the Biobase of the Department of Physiology, Iuliu Hatieganu University of Medicine and Pharmacy, Cluj-Napoca, Romania, 2012

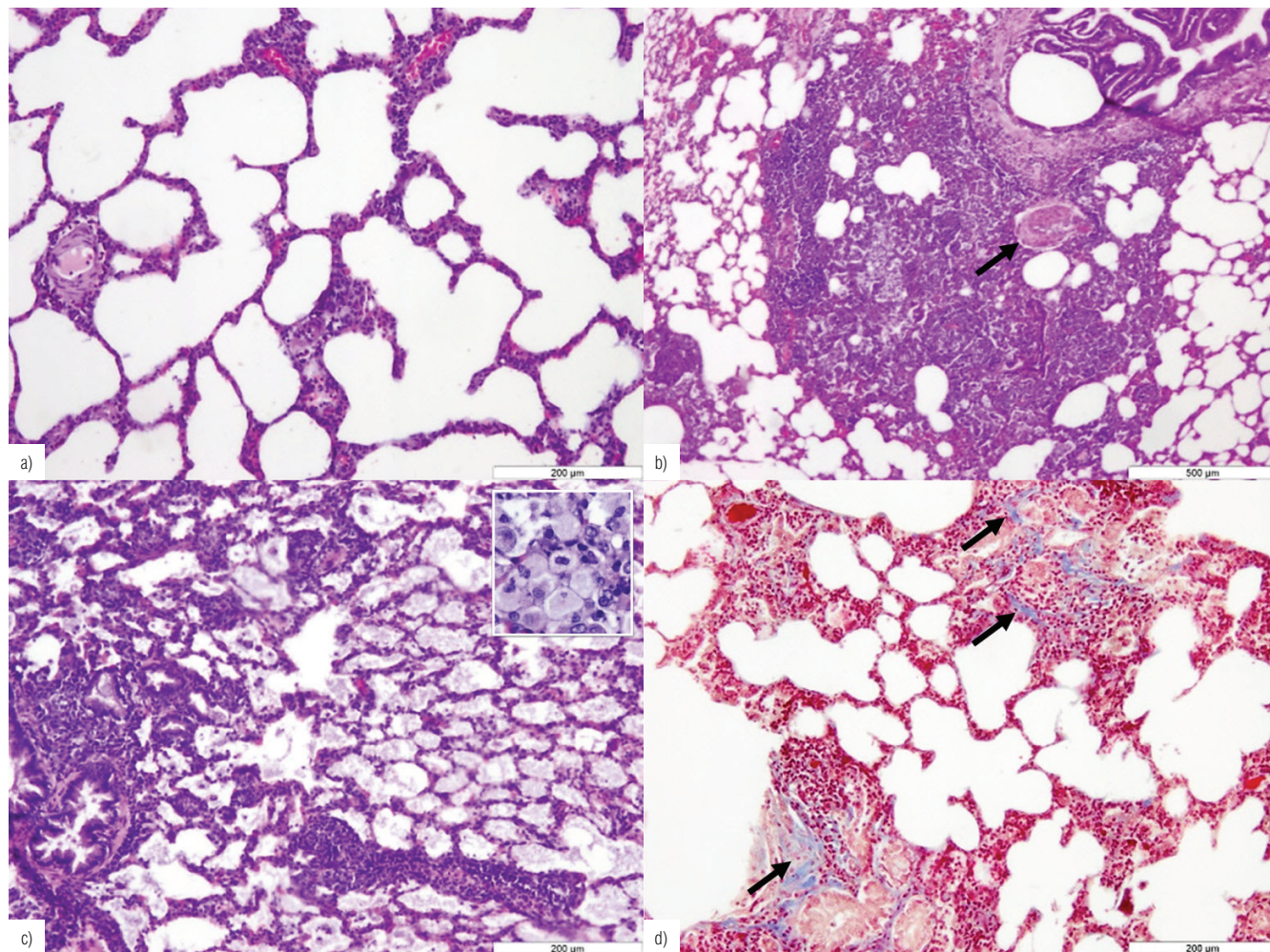
Variable	Concentration (M±SD)	P					
		control	SiO <sub>2</sub> .30	SiO <sub>2</sub> .90	SiO <sub>2</sub> .90+C	SiO <sub>2</sub> .120	SiO <sub>2</sub> .120+C
<b>MDA [nmol/mg protein]<sup>a</sup></b>							
control group							
tissue	0.25±0.04	–	0.0001	0.0055	0.47	<0.0001	0.06
blood	1.69±0.54	–	<0.0001	<0.0001	0.0017	<0.0001	<0.0001
SiO <sub>2</sub> .30 group							
tissue	0.37±0.06	0.0001***	–	0.22	0.0011	0.08	0.43
blood	4.43±0.95	<0.0001***	–	0.7199	0.0002	0.5831	0.2222
SiO <sub>2</sub> .90 group							
tissue	0.44±0.14	0.0055	0.22	–	0.007	0.97	0.06
blood	4.58±0.81	<0.0001***	0.7199	–	0.0001	0.9131	0.0803
SiO <sub>2</sub> .90+C group							
tissue	0.27±0.04	0.47 <sup>NS</sup>	0.0011	0.007	–	0.0002	0.08
blood	2.53±0.36	0.0017**	0.0002	0.0001	–	<0.0001	<0.0001
SiO <sub>2</sub> .120 group							
tissue	0.44±0.08	<0.0001***	0.08	0.97	0.0002	–	0.06
blood	4.62±0.35	<0.0001***	0.5831	0.9131	<0.0001	–	0.0085
SiO <sub>2</sub> .120+C group							
tissue	0.34±0.10	0.06	0.43	0.06	0.08	0.06	–
blood	3.92±0.48	<0.0001***	0.2222	0.0803	<0.0001***	0.0085	–
<b>CPs</b>							
control group							
tissue	1.53±0.95	–	0.0003	0.0629	0.0163	0.0258	0.1197
blood	2.28±0.93	–	0.3343	0.3162	0.2836	0.1081	0.2509
SiO <sub>2</sub> .30 group							
tissue	3.81±1.21	0.0003***	–	0.065	0.0369	0.1761	0.0258
blood	1.90±0.74	0.3343	–	0.9985	0.9546	0.0547	0.0299
SiO <sub>2</sub> .90 group							
tissue	2.59±1.31	0.0629	0.065	–	0.9098	0.6618	0.7045
blood	1.90±0.55	0.3162	0.9985	–	0.9441	0.0516	0.0173
SiO <sub>2</sub> .90+C group							
tissue	2.66±0.79	0.0163**	0.0369	0.9098	–	0.6689	0.5404
blood	1.88±0.49	0.2836	0.9546	0.9441	–	0.0489	0.0121
SiO <sub>2</sub> .120 group							
tissue	2.90±1.34	0.0258*	0.1761	0.6618	0.6689	–	0.4163
blood	3.82±2.11	0.1081	0.0547	0.0516	0.0489	–	0.2572
SiO <sub>2</sub> .120+C group							
tissue	2.36±1.09	0.1197	0.1228	0.7045	0.5404	0.4163	–
blood	2.78±0.71	0.2509	0.0299	0.0173	0.0121	0.2572	–

**Table 2.** The dynamics of the malonyldialdehyde (MDA), carbonyl proteins (CPs), thiolic proteins (TPs) and reduced glutathione (GSH) levels in the lung tissue and blood of animals in the experimental study performed in the Biobase of the Department of Physiology, Iuliu Hatieganu University of Medicine and Pharmacy, Cluj-Napoca, Romania, 2012 – cont.

Variable	Concentration (M±SD)	P					
		control	SiO <sub>2</sub> .30	SiO <sub>2</sub> .90	SiO <sub>2</sub> .90+C	SiO <sub>2</sub> .120	SiO <sub>2</sub> .120+C
<b>TPs [μmol/ml]</b>							
control group							
tissue	0.032±0.006	–	0.0025	0.4177	0.0943	0.0177	0.6326
blood	0.18±0.0	–	0.0104	0.0867	0.0131	0.0001	0.0004
SiO <sub>2</sub> .30 group							
tissue	0.024±0.003	0.0025**	–	0.3745	0.0041	0.7321	0.1228
blood	0.13±0.03	0.0104*	–	0.2889	0.9794	0.0039	0.0552
SiO <sub>2</sub> .90 group							
tissue	0.028±0.01	0.4177	0.3745	–	0.0838	0.4694	0.3671
blood	0.14±0.04	0.0867	0.2889	–	0.2972	0.0009	0.0079
SiO <sub>2</sub> .90+C group							
tissue	0.039±0.010	0.0943	0.0041	0.0838	–	0.0051	0.6049
blood	0.13±0.03	0.0131**	0.9794	0.2972	–	0.0034	0.0428
SiO <sub>2</sub> .120 group							
tissue	0.025±0.005	0.0177*	0.7321	0.4694	0.0051	–	0.1443
blood	0.07±0.03	0.0001***	0.0039	0.0009	0.0034	–	0.0775
SiO <sub>2</sub> .120+C group							
tissue	0.035±0.016	0.6326	0.1228	0.3671	0.6049	0.1443	–
blood	0.10±0.02	0.0004***	0.0552	0.0079	0.0428	0.0775	–
<b>Reduced GSH [nmol/mg protein]</b>							
control group							
tissue	1.05±0.36	–	0.0022	0.022	0.3286	0.073	0.7028
blood	6.76±1.02	–	<0.0001	<0.0001	0.3701	<0.0001	0.8371
SiO <sub>2</sub> .30 group							
tissue	0.57±0.07	0.0022	–	0.0025	0.048	0.028	0.0146
blood	2.99±1.20	<0.0001***	–	0.4471	<0.0001	0.2324	<0.0001
SiO <sub>2</sub> .90 group							
tissue	0.73±0.10	0.022	0.0025	–	0.0118	0.7449	0.0799
blood	2.60±0.81	<0.0001***	0.4471	–	<0.0001	0.5537	<0.0001
SiO <sub>2</sub> .90+C group							
tissue	0.92±0.16	0.3286	0.048	0.0118	–	0.0641	0.6237
blood	6.31±1.01	0.3701	<0.0001	<0.0001	–	<0.0001	0.2945
SiO <sub>2</sub> .120 group							
tissue	0.75±0.17	0.073	0.028	0.7449	0.0641	–	0.1112
blood	2.37±0.58	<0.0001***	0.2324	0.5537	<0.0001	–	<0.0001
SiO <sub>2</sub> .120+C group							
tissue	0.98±0.31	0.7028	0.0146	0.0799	0.6237	0.1112	–
blood	6.86±0.91	0.8371	<0.0001	<0.0001	0.2945	<0.0001	–

ª Significance of the differences when compared to control: n.s. – non-significant, \* p < 0.005, \*\* p < 0.001, \*\*\* p < 0.0001. Group explanations as in Table 1.





a – normal lung histology, hematoxylin-eosin (HE) stain.

b – peribronchiolar silicotic nodule with increased parenchymal cellularity, thickening of the septae, medial hypertrophy of an artery (arrow), HE stain.

c – intraalveolar protein material accumulation, mild multifocal septal cellular infiltration, alveolar histiocytosis (inset), HE stain.

d – mild, multifocal areas of septae thickened by inflammatory infiltrates and multifocal, mild interstitial fibrosis (arrows). Masson's trichrome stain.

Group explanations as in Table 1.

**Figure 1.** Lung tissue of Wistar rats in groups: a) control, b) SiO<sub>2</sub>.90+C, c) SiO<sub>2</sub>.120, and d) SiO<sub>2</sub>.120

the vascular changes. Minimal focal fibrosis confirmed with Masson's trichrome stain (Figure 1d) was only seen in group 5 (SiO<sub>2</sub>.120).

The semi-quantitative histopathologic evaluation is detailed in Table 3 and is based upon the severity and distribution of alveolitis, the epithelial alveolar hypertrophy/hyperplasia and the lipoproteinosis. It can be observed that the average score for all 3 histopathological descriptive elements is continuously rising throughout the experiment. Curcumin significantly improved the alveolar process and the lipoproteinosis component on day 90 and, to a lower extent, the alveolar epithelial hypertrophy/hyperplasia. The effect was much more pronounced on day 120 for all the 3 histopathologic parameters.

## DISCUSSION

The authors' goal was to investigate the development of changes in oxidative stress markers in the 2 environments (blood and tissue), correlated with histopathological changes, and also to find out how curcumin administration influenced them. The authors managed to confirm the early onset of oxidative stress after silica instillation, a crucial phenomenon for promoting inflammation and silica-induced fibrosis. The most significant changes in the studied biomarkers were the increase in MDA and the decrease in the GSH blood levels, i.e., aspects like those described by Orman et al, [19] in a clinical study. The rise in the MDA concentration as an expression of the lipoperoxidation of unsaturated fatty

**Table 3.** The results of the histopathologic evaluation of the lung tissue for each group of the experimental study performed in the Biobase of the Department of Physiology, Iuliu Hatieganu University of Medicine and Pharmacy, Cluj-Napoca, Romania, 2012

Group	Histopathologic evaluation score (M)		
	alveolitis	alveolar epithelium hypertrophy/hyperplasia	lipoproteinosis
Control	0.1	0.1	0
SiO <sub>2</sub> ,30	4.7	5	4.4
SiO <sub>2</sub> ,90	6.9	6.65	6.45
SiO <sub>2</sub> ,90+C	6.25	6.2	5.95
SiO <sub>2</sub> ,120	7.8	7.35	7.5
SiO <sub>2</sub> ,120+C	4.75	4.2	4.1

Group explanations as in Table 1.

acids (through oxidative attack on the membranes) is considered a valuable biomarker in the research of oxidative stress in clinical studies on silicosis [1,2,20], as well as in experimental ones [21].

There is little data in literature regarding the concurrence between the values of diverse biomarkers of oxidative stress recorded in blood and several tissues [3,22], but the authors did not find references on the blood/lung tissue correspondence. According to their observations, the blood levels for MDA, TPs and GSH as biomarkers for oxidative stress truthfully reflect the events in the lung tissue, with some reserves regarding CPs. To the best of their knowledge, the present study contains the first approach on the blood/pulmonary tissue match for the research of oxidative stress biomarkers in silicosis and the effects of curcumin administration.

The decrease in the MDA levels and the increase in the GSH content, both in the lung tissue as well as in blood, noted in the animals treated with curcumin, suggest a protective effect of this product, a fact also supported by the improvement in the lesion score noted in the histopathological study. The protective effect could be explained by the antioxidative and anti-inflammatory action of curcumin. According to some observations, curcumin reduces the silica toxicity with a consecutive decrease in the formation rate for ROS and inhibits the secretion of the inflammatory mediators in stimulated macrophages [12,23]. The anti-inflammatory effect also explains the encouraging results obtained in clinical [24] and experimental studies about rheumatoid arthritis and some autoimmune inflammatory diseases [12,25]. The few experimental considerations respecting the use of curcumin with exposure to silica proved an anti-inflammatory [23] and antifibrosis effect [26], but also mentioned the risk for DNA damage [23].

Histologically, only some lungs on day 120 after silica instillation revealed very mild fibrosis and, at this experimental stage, the majority of the silicotic nodules were of a cellular type. Castranova et al. [27] previously described a biphasic response to silica inhalation: during the first 41 days of exposure to silica, they constantly noted inflammatory changes and lesions without fibrosis, followed on 41 to 116 days after exposure by a rapid rise in pulmonary inflammation with a simultaneous development of fibrosis. This discrepancy could be the result of the difference in the method of exposure to silica, the inhalation of a 15 mg/m<sup>3</sup> silica concentration used by Castranova et al. [27] being possibly superior to the single instillation, with a relatively small dose, as was used in this experiment.

The airway and blood vessels remodeling effect proved to be early and occurred prior to fibrosis. This process started by silica-induced inflammation very likely represents the basis of peripheral airway obstruction in subjects exposed to quartz dust, with or without radiological signs of silicosis. Some experimental studies have confirmed that mineral dusts can directly induce fibrotic changes in airway walls [28]. Churg et al. [29] noted a small airway remodeling on a group of Mexico City females exposed to particulate materials. The observations made by the authors of this article, in agreement with the ones mentioned, suggest that inflammation caused by silica particles could be a common link for the events taking place at the interstitial level (where it directs the histogenesis of the silicotic nodules) and the peripheral airway level (where it determines remodeling and obstruction). Vascular remodeling accompanied by arterial obliterative lesions can determine lung hypertension throughout the course of silicosis.



It is more difficult to explain why curcumin did not influence the lesions characteristic of the airway and blood vessel remodeling process. Probably these areas are more reactive than the rest of the lung parenchyma and represent sites that allow the development of a dense cellularity with proinflammatory cytokine secretion potential. At the level of terminal bronchioles, there is a concentration of air pollutants deposited in the alveolar territory, from where they are retrogradely vehiculated by clearance mechanisms. The pulmonary sumps develop in this area, their role being to retrieve the surfactant, thus concentrating the inhaled dust with the development of maximal effect on this site. In favor of this supposition, Pinkerton [30] formulated his findings on a group of autopsied men with a significant remodeling of the terminal and respiratory bronchioles coinciding with an accumulation of dust, mostly at the level of first-generation bronchioles.

One limitation of this research might be the use of just 1 control group, euthanized on day 30, as the oxidative stress parameters may change during 3 months of life.

## CONCLUSIONS

The present study illustrates a good blood/lung tissue relation of the MDA, TP and GSH levels, which are markers used for evaluating silicosis-induced oxidative stress, a positive effect of curcumin shown by the decrease in the oxidative stress and an amelioration of the histology lesion score, but without any influence on the airway and blood vessel remodeling.

## REFERENCES

- Zhang JW, Lv GC, Yao JM, Hong XP. Assessment of serum antioxidant status in patients with silicosis. *J Int Med Res.* 2010;38(3):884–9, <https://doi.org/10.1177/147323001003800314>.
- Miao RM, Zhang XT, Guo P, He EQ, Zhou F, Zhao DK, et al. Effect of oxidative stress on development of silicosis. *World J Respirol.* 2012;2(1):1–5, <https://doi.org/10.5320/wjr.v2.i1.1>.
- Veskoukis AS, Nikolaidis MG, Kyparos A, Kouretas D. Blood reflects tissue oxidative stress depending on biomarker and tissue studied. *Free Radic Biol Med.* 2009;47(10):1371–4, <https://doi.org/10.1016/j.freeradbiomed.2009.07.014>.
- Zelko IN, Zhu J, Roman J. Role of SOD3 in silica-related lung fibrosis and pulmonary vascular remodeling. *Respir Res.* 2018;19(1):221, <https://doi.org/10.1186/s12931-018-0933-6>.
- Castranova V. Signalling pathways controlling the production of inflammatory mediators in response to crystalline silica exposure: role of reactive oxygen/nitrogen species. *Free Radic Biol Med.* 2004;37(7):916–25, <https://doi.org/10.1016/j.freeradbiomed.2004.05.032>.
- Fukui H, Endoh S, Shichiri M, Ishida N, Hagihara Y, Yoshida Y, et al. The induction of lipid peroxidation during the acute oxidative stress response induced by intratracheal instillation of fine crystalline silica particles in rats. *Toxicol Ind Health.* 2016;32(8):1430–7, <https://doi.org/10.1177/0748233714564415>.
- He JL, Zhang JW, Lv GC, Zhao Y, Hong XP. Study on serum oxidative stress status in silicosis patients. *Afr J Biotechnol.* 2011;10(51):10504–8, <https://doi.org/10.5897/AJB10.1937>.
- Vallyathan V, Leonard S, Kuppusamy P, Pack D, Chzhan M, Sanders SP. Oxidative stress in silicosis: evidence for the enhanced clearance of free radicals from whole lungs. *Mol Cell Biochem.* 1997;168(1–2):125–32, <https://doi.org/10.1023/a:1006850920080>.
- Vallyathan V, Castranova V, Pack D, Leonard S, Shumaker J, Hubbs AF. Freshly fractured quartz inhalation leads to enhanced lung injury and inflammation. Potential role of free radicals. *Am J Respir Crit Care Med.* 1995;152(3):1003–9, <https://doi.org/10.1164/ajrccm.152.3.7663775>.
- Chia KS, Ng TP, Jeyaratnam J. Small airways function of silica-exposed workers. *Am J Ind Med.* 1992;22(2):155–62, <https://doi.org/10.1002/ajim.4700220203>.
- Zhou H, Beevers CS, Huang S. The targets of curcumin. *Curr Drug Targets.* 2011;12(3):332–47, <https://doi.org/10.2174/138945011794815356>.
- Lee KH, Chow YL, Sharmili V, Abas F, Alitheen NB, Shaari K, et al. BDMC33, A Curcumin Derivative Suppresses Inflammatory Responses in Macrophage-Like Cellular System: Role of Inhibition in NF- $\kappa$ B and MAPK Signaling Pathways. *Int J Mol Sci.* 2012;13(3):2985–3008, <https://doi.org/10.3390/ijms13032985>.
- Shehzad A, Rehman G, Lee YS. Curcumin in inflammatory diseases. *Biofactors.* 2013;39(1):69–77, <https://doi.org/10.1002/biof.1066>.
- Conti M, Morand PC, Levillain P, Lemonnier A. Improved fluorometric determination of malonaldehyde. *Clin Chem.* 1991;37(7):1273–5.
- Reznic AZ, Packer L. Oxidative damage to proteins. Spectrophotometric method for carbonyl assay. *Methods Enzymol.* 1994;233:357–63, [https://doi.org/10.1016/s0076-6879\(94\)33041-7](https://doi.org/10.1016/s0076-6879(94)33041-7).
- Hu ML. Measurement of protein thiol groups and glutathione in plasma. *Methods Enzymol.* 1994;233:380–5, [https://doi.org/10.1016/s0076-6879\(94\)33044-1](https://doi.org/10.1016/s0076-6879(94)33044-1).



17. Bradford MM. A rapid and sensitive method for the quantitation of microgram quantities of protein utilizing the principle of protein-dye binding. *Anal Biochem.* 1976; 72:248–54, <https://doi.org/10.1006/abio.1976.9999>.
18. Porter DW, Ramsey D, Hubbs AF, Battelli L, Ma J, Barger M, et al. Time course of pulmonary response of rats to inhalation of crystalline silica: histological results and biochemical indices of damage, lipidosis, and fibrosis. *J Environ Pathol Toxicol Oncol.* 2001;20(Suppl 1):1–14, <https://doi.org/10.1615/JEnvironPatholToxicolOncol.v20.iSuppl.1.10>.
19. Orman A, Kahraman A, Cakar H, Ellidokuz H, Serteser M. Plasma malondialdehyde and erythrocyte glutathione levels in workers with cement dust-exposure. *Toxicology.* 2005;207(1):15–20, <https://doi.org/10.1016/j.tox.2004.07.021>.
20. Azari MR, Ramazani B, Mosavian MA, Mohavadi M, Salehpour S. Serum malondialdehyde and urinary neopterin levels in glass sandblasters exposed to crystalline silica aerosols. *Int J Occup Hyg.* 2011;3(1):29–32, <https://doi.org/magiran.com/p899440>.
21. Zhu Z, Yang G, Wang Y, Yang J, Gao A, Niu P, et al. Suppression of thioredoxin system contributes to silica-induced oxidative stress and pulmonary fibrogenesis in rats. *Toxicol Lett.* 2013;222(3):289–94, <https://doi.org/10.1016/j.toxlet.2013.08.004>.
22. Arguelles S, Garcia S, Maldonado M, Machado A, Ayala A. Do the serum oxidative stress markers provide a reasonable index of the general oxidative stress status? *Biochim Biophys Acta.* 2004;1674(3):251–9, <https://doi.org/10.1016/j.bbagen.2004.06.023>.
23. Li H, van Berlo D, Shi T, Speit G, Knaapen AM, Borm PJ, et al. Curcumin protects against cytotoxic and inflammatory effects of quartz particles but causes oxidative DNA damage in a rat lung epithelial cell line. *Toxicol Appl Pharmacol.* 2008;227(1):115–24, <https://doi.org/10.1016/j.taap.2007.10.002>.
24. Chandran B, Goel A. A randomized, pilot study to assess the efficacy and safety of curcumin in patients with active rheumatoid arthritis. *Phytother Res.* 2012;26(11):1719–25, <https://doi.org/10.1002/ptr.4639>.
25. Jackson JK, Higo T, Hunter WL, Burt HM. The antioxidants curcumin and quercetin inhibit inflammatory processes associated with arthritis. *Inflamm Res.* 2006;55(4):168–75, <https://doi.org/10.1007/s00011-006-0067-z>.
26. Jiang ZY, Yue L, Lu YR, Dong J, Dai GK, Yang C. Curcumin inhibits SiO<sub>2</sub>-induced pulmonary fibrosis in mice. *Chin J Pathophysiol.* 2009;25(5):976–9.
27. Castranova V, Porter D, Millecchia L, Ma JY, Hubbs AF, Teass A. Effect of inhaled crystalline silica in a rat model: time course of pulmonary reactions. *Mol Cell Biochem.* 2002;234-235(1–2):177–84, <https://doi.org/10.1023/A:1015967017103>.
28. Churg A, Wright JL. Airway wall remodelling induced by occupational mineral dusts and air pollutant particles. *Chest.* 2002;122(6 Suppl):306S–9S, [https://doi.org/10.1378/chest.122.6\\_suppl.306S](https://doi.org/10.1378/chest.122.6_suppl.306S).
29. Churg A, Brauer M, del Carmen Avila-Casado M, Fortoul TI, Wright JL. Chronic exposure to high levels of particulate air pollution and small airway remodeling. *Environ Health Perspect.* 2003;111(5):714–8, <https://doi.org/10.1289/ehp.6042>.
30. Pinkerton KE, Green FH, Saiki C, Vallyathan V, Plopper CG, Gopal V, et al. Distribution of particulate matter and tissue remodeling in the human lung. *Environ Health Perspect.* 2000;108(11):1063–9, <https://doi.org/10.1289/ehp.001081063>.