

CARDIOVASCULAR SCREENING OF ELDERLY ATHLETES

Robert Skalik¹, Anna Janocha²

¹ Medical Centre PZU Health, Wrocław, Poland

² Wrocław University of Science and Technology, Wrocław, Poland
Faculty of Medicine

ABSTRACT

The permanently growing interest in amateur and professional sports activities among young, middle-aged and elderly athletes raises serious concerns about athletes' health, the safety of physical training, and the sports-related risk of sudden cardiac death and other cardiovascular complications during exercise. In recent years there has been an increasing number of cases of sudden cardiac death during physical effort. At present, life expectancy in the most developed countries grows rapidly and the number of people >65 years dramatically increases. Moreover, biological age of the population is lower. Subsequently, relevant increase in the number of elderly athletes involved in various types of sports activities has been reported in many countries. It was also demonstrated that physical activity has strong beneficial effect on cognitive functions, psychomotor performance and thus exercise capacity, which is very important for the elderly people in their everyday routine activities. Nonetheless, it should be remembered that participation in amateur and professional sports activities may be associated with risk of serious cardiovascular events in the elderly athletes often suffering from various civilization diseases. It is also reported that the number of elderly people after interventional cardiology procedures, open heart surgery and cancer treatment (chemotherapy, radiotherapy), who wish to participate in various sports activities, systematically grows. The authors of the paper conduct a literature review on cardiovascular risk assessment in the elderly athletes including the contemporary cardiology diagnostic methods and diagnostic schemes to prevent sudden cardiac death and other cardiovascular events during exercise. The controversies over efficacy of particular diagnostic tools to detect cardiovascular diseases in the elderly athletes and worldwide epidemiologic data concerning risk of sudden cardiac death during physical exercise have been also presented. Here, the authors have derived suggestions for establishment of comprehensive diagnostic schemes to prevent sudden cardiac death during sports activities. *Med Pr Work Health Saf.* 2024;75(3):233–241

Key words: cardiovascular diseases, physical activity, sudden cardiac death, cardiovascular complications, elderly athletes, cardiovascular screening

Corresponding author: Anna Janocha, Wrocław University of Science and Technology, Faculty of Medicine, Hoene-Wrońskiego 13c, 58-376 Wrocław, Poland, e-mail: anna.janocha@pwr.edu.pl
Received: December 14, 2023, accepted: February 16, 2024

INTRODUCTION

The number of the elderly people (persons aged ≥ 65 years) involved in various sports activities permanently increases in the industrialized countries. However, the growing number of cases of sudden cardiac death among athletes during sports competition has been recently reported across the globe [1]. Nowadays, life expectancy in the most developed countries grows rapidly and the number of elderly people will also dramatically rise in the nearest future [2]. As a result, the number of elderly athletes participating in numerous sports disciplines has increased in many countries.

In recreational sports, the incidence of cardiovascular fatalities will especially rise in the elderly population [3]. The risk of heart damage or chronic heart failure in athletes increases with age [4,5]. Furthermore, a relevant number of patients with a history of cardiotoxic

cancer treatment (chemotherapy or radiotherapy) intend to exercise [6]. For this reason, sports cardiologists will have to qualify more and more patients with a relevant cardiovascular burden for various sports disciplines.

It is reported that atherosclerotic coronary artery disease is the leading cause of sudden cardiac death or cardiovascular complications in the elderly athletes [7,8]. In addition, some valve defects (severe aortic stenosis, mitral prolapse with relevant mitral regurgitation) and heart failure of various aetiologies (ischemic, post-inflammatory, chemotherapy-related or toxic cardiomyopathy) can also contribute to cardiovascular events in the elderly people [9]. These cardiac pathologies may be asymptomatic in many cases. Moreover, resting electrocardiography and physical examination can be normal in some valve defects and cardiac dysfunction [10,11]. The myocarditis or myocardial ischemia

can induce acute heart failure in the old athletes participating in strenuous physical effort [10,12].

Severe exercise may cause heart dysfunction and then induce life threatening arrhythmias in the predisposed elderly athletes [13]. Mental stress and the enhanced activity of sympathetic nervous system while severe exercise as combined with heat stress, hypothermia, dehydration and electrolyte imbalance can bring about enormous release of catecholamines into the circulation that can be a trigger for cardiac dysfunction, cardiovascular collapse or even heart arrest in this group of athletes [10,14,15].

Some sports disciplines (e.g., marathon running, basketball, soccer, tennis) are related to huge energy demand that is an enormous burden on cardiovascular system. The significant increase in heart rate, cardiac output and arterial blood pressure is observed during physical effort in healthy athletes [10]. This physiologic adaptive response results from elevated demand for oxygen by skeletal muscles during acute exercise [10]. Thus, the unrecognized cardiac dysfunction caused by multiple harmful factors affecting the efficiency of tissue metabolism and cardiovascular system (e.g., atherosclerosis, diabetes, arterial hypertension, renal dysfunction, medicines, doping, exercise-induced hyperthermia, dehydration, electrolyte imbalance or cytokines release by working skeletal muscles) may determine exercise performance and further contribute to cardiovascular fatalities in some circumstances [16,17]. Hence, a detailed screening of the elderly athletes including basic laboratory tests and advanced cardiovascular diagnostic techniques is obviously needed, including:

- basic laboratory tests: thyroid stimulating hormone (TSH), C-reactive protein (CRP), blood morphology, electrolytes, troponin and creatine kinase MB (CK-MB) tests – diagnosis of myocardial infarction, myocarditis; N-terminal prohormone of brain natriuretic peptide (NT-proBNP) or brain natriuretic peptide (BNP) – diagnosis of heart failure; D-dimers – suspicion of pulmonary embolism, deep vein thrombosis;
- chest X-ray, spirometry, blood oxygen saturation – suspicion of chronic obstructive pulmonary disease (COPD), emphysema, exudative pleuritis that may coincide with heart diseases in the elderly athletes;
- resting electrocardiography – diagnosis of arrhythmias, coronary artery disease, valve defects, cardiomyopathies;
- echocardiography – suspicion of heart failure, coronary artery disease, cardiomyopathies, valve defects, atrial septal defect (ASD), ventricular septal defect (VSD);

- electrocardiography Holter monitoring (Holter ECG) – diagnosis of arrhythmias like atrial fibrillation, ventricular tachycardia, conduction disturbances;
- ambulatory blood pressure monitoring (ABPM) – diagnosis of arterial hypertension;
- cardiopulmonary exercise testing (CPET) – objective assessment of exercise capacity in athletes;
- cardiac computed tomography (CCT) – diagnosis of coronary artery disease, valve defects;
- cardiac magnetic resonance imaging (CMRI) – differentiation between ischemic and non-ischemic cardiomyopathy, inflammatory or metabolic cardiac dysfunction such as cardiac sarcoidosis, amyloidosis, hemochromatosis, myocarditis, pericarditis.

In the review article, the authors present the recent advances in cardiovascular screening of the elderly athletes, methods to qualify this population for various types of sports activities, including the standard and most sophisticated diagnostic techniques, epidemiological data and sports-related cardiovascular risk assessment scheme.

METHODS

The goal of this paper is to evaluate the published evidences about the relevance of detailed cardiovascular pre-participation screening of the elderly athletes, including eligible cardiovascular diagnostics tools and methods (familial history, physical examination, symptomatology, electrocardiography, echocardiography, cardiac magnetic resonance, cardiac computed tomography, ECG exercise test, cardiopulmonary exercise testing) for the detection of life-threatening cardiovascular diseases and summarize findings across the studies on sports-related risk of sudden cardiac death. The authors reviewed the published literature by searching for relevant publications in Google Scholar and MEDLINE (PubMed) databases using the following key phrases: „sudden cardiac death,” „elderly athletes,” „cardiovascular screening of athletes” and „pre-participation screening of athletes.” The review included articles published between 2000–2023.

RESULTS

Risk of sudden cardiac death in the elderly athletes

In spite of the undisputed health benefits of sports activity, strenuous physical effort may paradoxically increase the risk of acute cardiovascular events in some elderly

athletes. The risk of sudden cardiac death (SCD) almost doubles during physical activity and is 2- to 3-fold higher in athletes compared to non-athletes. The incidence of SCD in young athletes is very low (1–3 deaths per 100 000 athletes) [18,19]. However, the incidence of SCD in the elderly athletes is higher and will probably rise, because more and older individuals want to participate in various sports disciplines. Marijon et al. [20] reported that overall burden of sports-related sudden death was 4.6 cases per million population per year. The crushing majority of SCD cases (>90%) occurred in the recreational sports, with only 6% of cases occurring in young competitive athletes [20]. There is a strong link between the risk of SCD and the age of athlete. According to Chugh and Weiss [21], the risk of sports-related SCD is highest in athletes aged 40–70 years. The SCD is often the first clinical manifestation of a potentially fatal underlying cardiovascular disorder and usually occurs in previously asymptomatic athletes.

Familial history of cardiovascular diseases and specificity of symptoms in the elderly athletes

The crushing majority of sports-related cardiovascular fatalities are caused by genetically conditioned diseases, therefore familial history of cardiovascular pathologies is of the utmost importance for the early detection of at risk individuals [10,22]. Hence, the athletes presenting with the familial history of sudden death or premature heart attack (<55 years of age in males and <65 years in females), cardiomyopathy (ischemic, post-inflammatory or hypertrophic cardiomyopathy), long and short QT syndrome, Brugada syndrome, severe arrhythmias, Marfan syndrome, coronary artery disease should undergo the detailed pre-participation cardiovascular screening (resting ECG, echocardiography, ECG Holter monitoring, ECG exercise test or eventually cardiac magnetic resonance and cardiac computed tomography). Several athletes with congenital cardiac pathologies (e.g., arrhythmogenic right ventricular cardiomyopathy) may not have preceding symptoms of the disease [23].

The familial history of cardiovascular diseases must be contemplated in the case of following symptoms in the elderly athletes: exertional chest pain or discomfort, syncope or pre-syncope, irregular heartbeat or palpitations, dizziness, shortness of breath or fatigue disproportionate to the degree of physical effort [24]. However, the clinical manifestation of cardiovascular disorders in this population can be sometimes non-specific or unusual. The non-cardiac chest pain may also be a symptom

of congenital or acquired heart defects (e.g., bicuspid aortic valve, aortic dilatation or aneurysm of the ascending aorta) and should be diagnosed before regular physical activity is initiated or resumed [10].

The ambitious elderly athletes in particular are inclined to dissimulate their symptoms or blame them on non-cardiac causes. They often attribute their exertional shortness of breath to fatigue or ageing. The diagnostic process and management of heart diseases in this group of athletes can be compounded by some comorbidities such as COPD, diabetes mellitus, depression and the age-related impairment of cognitive functions [10]. The reduced exercise capacity is often ignored and attributed to overtraining. In some elderly athletes, cognitive impairment and drop in psychomotor performance can be also one of the first symptoms of chronic heart failure [25]. It has been corroborated that cognitive functions and brain processing are strongly associated with cardiovascular system and exercise performance on CPET both in healthy athletes and chronic heart failure [26–28]. The cognitive dysfunction is also a marker of poor prognosis in patients with chronic heart failure [29]. Moreover, cognitive functions can deteriorate in the elderly athletes with diabetes mellitus and depression, which may add to fatigue during exercise and the impairment of aerobic capacity in this population [30]. Resting electrocardiography, basic laboratory tests and biomarkers (troponin, NT-proBNP, BNP) are not always reliable in some athletes with chronic heart failure and other heart conditions [31–34].

The elderly athletes with normal physical examination, negative basic clinical tests results and persisting symptoms such as shortness of breath, unexpected decrease in exercise performance, fatigue and muscle pains of unknown origin, cognitive decline, syncopal episodes, legs swelling, cough, nocturia or oliguria, anginal and atypical chest pains, recent history of respiratory tract infection combined with the reduced exercise capacity, heart palpitations, must be interrogated with echocardiography, prolonged Holter ECG and eventually ECG stress test or CPET.

Screening tools to prevent sudden cardiac death and other cardiovascular events in the elderly athletes – controversies, screening methods and diagnostic modalities

Athletic training can cause tremendous overload of the cardiovascular system and thus become a trigger for fatal cardiovascular events in the elderly athletes with the undetected heart conditions [8]. Hence, every

athlete should undergo a detailed diagnostic examination before a training program is prescribed or continued. However, it is still a controversial issue which of the diagnostic tools should be routinely used to reduce the risk of sudden cardiac death or other cardiovascular complications in sports.

The conventional cardiovascular screening model in athletes includes resting ECG, physical examination and familial history of heart diseases. However, the diagnostic accuracy of the conventional model is controversial in some cases of cardiac disorders. Sports activities can induce some adaptive changes in the structure and function of heart as observed on echocardiography and ECG. Nonetheless, the physiologic changes referred to as the "athlete's heart" may coincide with structural heart diseases and be a drawback to the diagnostic process in some athletes. In the clinical setting, it is sometimes difficult to differentiate between adaptive physiology and cardiac pathology in athletes without use of advanced cardiac imaging techniques. An electrocardiogram can be normal in some elderly athletes with hypertensive hypertrophic cardiomyopathy, coronary artery disease, chronic heart failure or even acute myocarditis. The utility of resting electrocardiography for the diagnosis of many structural heart pathologies is limited, because ECG record is determined by numerous cardiac, extracardiac, cellular and physical factors (hormonal and electrolyte imbalance, autonomic dysregulation, body mass index, medication, doping, chest wall shape and size) [34].

On the other hand, the resting ECG and Holter ECG monitoring offer the huge diagnostic power to detect potentially lethal conditions related to congenital electrical heart dysfunction such as long and short QT syndrome, Brugada syndrome or Wolff-Parkinson-White (WPW) syndrome and various types of arrhythmias putting athletes at risk (ventricular tachycardia, heart conduction disturbances). Nonetheless, the above congenital conditions mainly account for sudden deaths in the young competitive athletes. In the elderly athletes, the crushing majority of sports-related cases of sudden cardiac death and other cardiovascular adverse events are caused by atherosclerotic coronary artery disease [7,8].

The acquired valve defects, aortic dilatation, undetected arterial hypertension, asymptomatic chronic heart failure, acute myocarditis or myocardial bridge may also contribute to some serious cardiovascular complications (brain stroke, acute myocardial infarction, pulmonary oedema, heart arrest, aortic rupture,

exercise-induced arrhythmias) during severe physical effort in this population [35]. The specificity and sensitivity of resting electrocardiography and physical examination for the detection of the cardiovascular diseases is low in many cases [34]. The normal resting ECG does not always preclude relevant cardiac pathology, albeit some electrocardiographic abnormalities found in the elderly athletes may not herald serious heart problem. The resting ECG abnormalities such as incomplete right bundle branch block, non-specific intraventricular conduction disturbances, atrial fibrillation and some others may not be a contraindication for sports participation. However, they can be also present in the elderly athletes with an acquired or congenital heart anomaly such as ASD, relevant aortic stenosis or mitral regurgitation [36]. The ECG abnormalities demanding in-depth investigation in the elderly athletes are listed below:

- negative T waves in leads: I, aVL, V1, V2, V5 and V6;
- pathological Q wave duration (>30 ms) or QS pattern in at least 2 leads;
- prolonged QT interval;
- pre-excitation syndrome;
- ventricular and supraventricular arrhythmias (extrasystoles, atrial fibrillation or flutter, ventricular tachycardia);
- features of right ventricular hypertrophy (qR complex in lead V1, S-wave voltage above the normal limit in lead I);
- right or left bundle branch block, right or left fascicular block, bifascicular block;
- pathological right axis deviation;
- sinus tachycardia or bradycardia, first-, second-, or third-degree atrioventricular block.

Some athletes with ASD can present with slight ECG abnormalities, i.e., incomplete right bundle branch block or unusual non-cardiac symptoms [37]. The complete diagnostics of heart defects always demands imaging techniques including echocardiography or even cardiac magnetic resonance. It is especially relevant for scuba diving candidates who may suffer from decompression illness and subsequent systemic embolism if an ASD remains undetected and untreated [34].

Steriotis et al. [38] showed that ECG stress test can induce dangerous ventricular arrhythmias in the relevant group of athletes with a normal resting ECG. It is reported that the diagnostic accuracy of a resting ECG for the detection of coronary artery disease in athletes is low at pre-participation screening [24]. In some elderly asymptomatic athletes with relevant coronary artery disease, ECG exercise test can be also inconclusive [39].

In these circumstances, athletes with high or very high risk of ischemic heart disease (familial history, diabetes mellitus, hyperlipidemia, nicotine addiction) and intention to participate in high intensity training should undergo cardiac computed tomography of coronary vessels to exclude relevant atherosclerotic lesions in the heart [34].

Rizzo et al. [40] argue that echocardiography significantly improves the diagnostic power of cardiovascular screening in the detection of serious cardiac conditions as compared with ECG and physical examination in athletes. Professional sports associations such as the NBA (National Basket Ball Association, USA) and NFL (National Football League, USA) have recommended echocardiography in the routine screening of athletes [41]. In most European countries, Olympic athletes undergo regular medical check-ups including cardiac ultrasound examination [34].

At present, echocardiography with advanced imaging techniques (tissue doppler echocardiography, strain rate imaging, stress echocardiography, 3D-echocardiography) is a basic screening tool for sports cardiologists to detect cardiac anomalies posing a grave risk for the elderly athletes, i.e., contractile heart dysfunction, systolic or diastolic heart failure, acquired and congenital cardiac defects, and perform reliable risk stratification in the elderly athletes [8]. Echocardiography (pulsed wave tissue doppler) can be also used to differentiate between adaptive exercise-induced thickening of cardiac muscle and pathologic hypertrophy in athletes [42]. In case of cardiac contractile dysfunction or heart failure as found on standard echocardiography in the elderly athletes, further more advanced diagnostic instruments such as cardiac computed tomography or cardiac magnetic resonance are needed to establish aetiology of cardiac muscle damage [10].

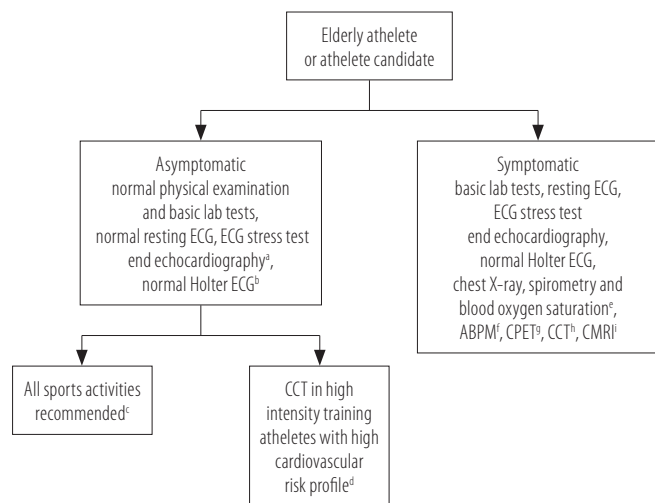
Coronary artery anomalies are another life-threatening heart disease that can be missed during conventional athlete screening with use of a resting ECG or even echocardiography and ECG stress test. Athletes with this cardiac pathology may not present with any symptoms for a long time, albeit they are at risk of sudden cardiac death during strenuous physical exercise. Coronary artery anomalies are predominantly diagnosed in young athletes, however this congenital cardiac pathology can be also responsible for sudden cardiac deaths in several elderly athletes. Coronary artery anomalies are sometimes discovered during invasive coronary angiography in patients diagnosed with atherosclerotic coronary artery disease [43]. In fact, cardiac

computed tomography is the only non-invasive reliable diagnostic tool for the detection of anomalous coronary arteries in the adult athletes.

It was previously demonstrated that regular physical exercise is associated with a lowered risk of cancer recurrence and a longer life expectancy after cancer was diagnosed. However, numerous cancer patients have to undergo cardiotoxic treatment (chemotherapy and radiotherapy) that can be a trigger for heart dysfunction and chronic heart failure many years after the effective cancer treatment was terminated. That is why recovered cancer patients planning to participate in various sports activities should be examined for heart dysfunction on the regular basis [10]. The subclinical impairment of cardiac function on strain rate imaging interrogation can herald symptomatic heart failure in the elderly athletes after cancer therapy [44]. It is predicted that almost 50% of patients with history of cancer therapy will suffer from heart dysfunction many years after cancer treatment, and unfortunately some of them will fall ill with chronic heart failure [10].

The unrecognised acute myocarditis in the elderly athletes can also culminate in acute heart failure during strenuous physical exercise [10]. The physical effort enhances activity of sympathetic nervous system and increases oxygen consumption by heart muscle, therefore it can contribute to the development of heart failure or induce hazardous ventricular arrhythmias in athletes with active myocarditis. The elderly athletes with a history of recent respiratory tract infection (flu, COVID-19), especially with persistent clinical symptoms (shortness of breath, fatigue, cough, heart palpitations), should undergo detailed medical examination (ECG, cardiac biomarkers, echocardiography or cardiac magnetic resonance in some unclear cases) [10,45]. It must be stressed that some athletes presenting with normal heart function after acute myocarditis may suffer from diastolic heart failure in the nearest future [46]. For this reason, elderly athletes after acute myocarditis should be examined for signs of heart failure by means of echocardiography [10].

The contemporary pre-participation cardiovascular screening model for prevention of sudden cardiac death in the elderly athletes consists of whole array of diagnostic tools including a resting ECG, ECG exercise test, Holter ECG monitoring and various diagnostic imaging modalities. The clinical application of particular diagnostic instruments in the elderly athletes should be based on risk factors of cardiovascular diseases, clinical symptoms and intensity of planned exercise (Figure 1).



ABPM – ambulatory blood pressure monitoring, CCT – cardiac computed tomography, CMRI – cardiac magnetic resonance imaging, CPET – cardiopulmonary exercise testing, ECG – electrocardiography.

^a No relevant valve defects or cardiac muscle dysfunction; athletes with mitral prolapse, mild mitral regurgitation and lack of exercise-induced arrhythmias can participate in sports activities. Mitral annulus disjunction (MAD) should be also evaluated on echocardiography.

^b No relevant arrhythmia – no bouts of atrial fibrillation or atrial flutter, ventricular tachycardia, numerous extrasystoles, advanced atrio-ventricular blocks.

^c If no extracardiac contraindications to participate in particular sports disciplines.

^d Coronary artery disease risk factors like cigarette smoking, diabetes, hyperlipidemia, familial history of ischemic heart disease, myocardial infarction or heart failure, arterial hypertension, physical inactivity, overweight or obesity.

^e Suspicion of chronic obstructive pulmonary disease, emphysema, exudative pleuritis that may coincide with heart diseases in the elderly athletes.

^f Diagnosis of arterial hypertension.

^g Diagnosis of detraining or overtraining, objective assessment of exercise capacity in athletes.

^h Diagnosis of coronary artery disease, valve defects.

ⁱ Differentiation between ischaemic and non-ischaemic cardiomyopathy, inflammatory or metabolic cardiac dysfunction.

Figure 1. Pre-participation screening model in the elderly athletes

CONCLUSIONS

The intensive physical effort can be a source of huge pressure on cardiovascular system that can cause the physiologic cardiac remodelling in healthy athletes (athlete's heart) [47]. However, heavy exercise may also induce heart failure or exacerbate pre-existing cardiac dysfunction in the elderly athletes with an unrecognized, underlying heart disease. Some athletes suffering from coronary artery disease, valve defect or chronic heart failure may present with atypical symptoms or be asymptomatic. Thus, the detailed diagnostic cardiovascular interrogation with use of sophisticated imaging tools can be needed both in symptomatic and asymptomatic athletes with high cardiovascular risk profile, who intend to participate in various sports activities.

There are some controversies among cardiologists over diagnostic screening models to prevent effectively

sudden cardiac death or cardiovascular complications in the elderly athletes. Nowadays, the process for selecting the reliable cardiovascular screening scheme in the elderly athletes or athlete candidates and the appropriate diagnostic instrumentation in this population should take into account additional factors as follows: the age-related prevalence of particular cardiovascular diseases, ethnicity, gender, type of sport discipline, exercise intensity (recreational vs. professional training, low vs. high intensity sports activities), presence of cardiovascular risk factors (smoking, diabetes, obesity, arterial hypertension, hyperlipidemia, a history of heart surgery, cardiology interventional procedure, drug addiction or doping, familial history of cardiovascular diseases), presence of clinical symptoms and the geographic distribution of particular cardiovascular diseases [34,48].

It must be concluded that the pre-participation cardiovascular screening in the elderly athletes should always include a resting ECG, physical examination as well as personal and familial history of heart conditions. However, the asymptomatic elderly athletes planning very intensive sports activities (e.g., skiing, gym activities, running, jogging, tennis, soccer) should also undergo ECG exercise test or cardiopulmonary exercise testing, Holter ECG and echocardiography to exclude coronary artery disease, heart failure, malicious arrhythmias, relevant acquired valve defect or congenital cardiac pathology. The cardiopulmonary exercise testing is also an invaluable tool to objectively assess exercise capacity and subsequently select an appropriate sport discipline adapted to the achieved maximal aerobic performance in the elderly athlete (low-, moderate-, or high-intensity sport).

Some of the asymptomatic athletes with numerous risk factors for coronary artery disease or the inconclusive results of the conventional diagnostics (resting ECG, echocardiography, ECG exercise test) should be referred for cardiac computed tomography or magnetic resonance imaging. Regarding the complexity of cardiovascular risk assessment in various sports disciplines and age groups, the optimal diagnostic screening model in the elderly athletes should be adapted to the cardiovascular burden in particular athletes and intensity of planned sports activities (Figure 1) [8,34].

The continual progress in the non-invasive cardiovascular diagnostic imaging techniques as observed within recent years, a more profound understanding of pathophysiology of many heart diseases and exercise physiology mechanisms facilitate cardiologists to detect the crushing majority of cardiac anomalies putting

athletes' life at risk. The properly planned exercise has been shown to be beneficial both for healthy persons and patients with chronic heart failure, ischemic heart disease, after cardiac surgery or interventional cardiology procedures [49]. Nonetheless, the risk of exercise-induced serious cardiovascular complications is high in the elderly athletes, who do not undergo an appropriate, evidence-based risk assessment examination supervised by a qualified sports cardiologist.

Author contributions

Research concept: Robert Skalik, Anna Janocha

Research methodology: Robert Skalik, Anna Janocha

Collecting material: Robert Skalik, Anna Janocha

Interpretation of results: Robert Skalik, Anna Janocha

References: Robert Skalik, Anna Janocha

REFERENCES

1. Egger F, Scharhag J, Kästner A, Dvořák J, Bohm P, Meyer T. FIFA Sudden Death Registry (FIFA-SDR): a prospective, observational study of sudden death in worldwide football from 2014 to 2018. *Br J Sports Med.* 2022;56(2):80-7. <https://doi.org/10.1136/bjsports-2020-102368>.
2. Kontis V, Bennett JE, Mathers CD, Li G, Foreman K, Ezzati M. Future life expectancy in 35 industrialised countries: projections with a Bayesian model ensemble. *Lancet.* 2017;389(10076):1323-35. [https://doi.org/10.1016/S0140-6736\(16\)32381-9](https://doi.org/10.1016/S0140-6736(16)32381-9).
3. Schmied C, Borjesson M. Sudden cardiac death in athletes. *J Intern Med.* 2014;275(2):93-103. <https://doi.org/10.1111/joim.12184>.
4. Ahmed A. DEFEAT – Heart Failure: a guide to management of geriatric heart failure by generalist physicians. *Minerva Med.* 2009;100(1):39-50.
5. Chen C, Sung KT, Shih SC, Liu CC, Kuo JY, Hou CJ, et al. Age, gender and load-related influences on left ventricular geometric remodeling, systolic mid-wall function, and NT-ProBNP in asymptomatic Asian population. *PLoS One.* 2016;11(6):e0156467. <https://doi.org/10.1371/journal.pone.0156467>.
6. Dimeo F. Exercise for cancer patients: a new challenge in sports medicine. *Br J Sports Med.* 2000;34(3):160-1. <https://doi.org/10.1136/bjism.34.3.160>.
7. Moorman AJ, Dean LS, Yang E, Jonathan A, Drezner JA. Cardiovascular risk assessment in the older athlete. *Sports Health.* 2021;13(6):622-9. <https://doi.org/10.1177/194173812111004877>.
8. Skalik R. Qualifying athletes for exercise. *e-Journal of Cardiology Practice.* 2014;12(29):1-10.
9. Marcoff L, Gillam LD. Aortic stenosis: risk stratification and timing of surgery. *Curr Cardiol Rep.* 2023;25(3):89-95. <https://doi.org/10.1007/s11886-022-01835-w>.
10. Skalik R, Furst B. Heart failure in athletes: pathophysiology and diagnostic management, *e-Journal of Cardiology Practice.* 2017;14(35):1-16.
11. Di Bella G, Florian A, Oreto L, Napolitano C, Todaro MC, Donato R, et al. Electrocardiographic findings and myocardial damage in acute myocarditis detected by cardiac magnetic resonance. *Clin Res Cardiol.* 2012;101(8):617-24. <https://doi.org/10.1007/s00392-012-0433-5>.
12. Deligiannis A, Björnstad H, Carre F, Heidbüchel H, Kouidi E, Panhuyzen-Goedkoop NM, et al. ESC study group of sports cardiology position paper on adverse cardiovascular effects of doping in athletes. *Eur J Cardiovasc Prev Rehabil.* 2006;13(5):687-94. <https://doi.org/10.1097/01.hjr.0000224482.95597.7a>.
13. La Gerche A, Connelly KA, Mooney DJ, MacIsaac AI, Prior DL. Biochemical and functional abnormalities of left and right ventricular function after ultra-endurance exercise. *Heart.* 2008;94(7):860-6. <https://doi.org/10.1136/hrt.2006.101063>.
14. Agostoni P, Cattadori G, Bianchi M, Wasserman K. Exercise-induced pulmonary edema in heart failure. *Circulation.* 2003;108:2666-71. <https://doi.org/10.1161/01.CIR.000097115.61309.59>.
15. Aoun J, Dgayli K, Zeid CA, Wong G, LaCamera P. Pulmonary edema during the Boston Marathon. *Respir Med Case Rep.* 2019;27:100845. <https://doi.org/10.1016/j.rmcr.2019.100845>.
16. Skalik R. Heat stress and psychomotor performance – neglected mechanisms of cardiopulmonary capacity in health and heart failure. *EC Cardiology.* 2017;4(1):10-3.
17. Skalik R, Borodulin-Nadzieja L, Woźniak W, Girek M, Kosendiak A, Janocha A. The significance of thermoregulation to physical capacity in humans – can dysregulation of core body temperature and its cortical perception have impact on the course of chronic heart failure? *Kardiol Pol.* 2009; 67(Suppl 6):449-54.
18. Corrado D, Basso C, Rizzoli G, Schiavon M, Thiene G. Does sports activity enhance the risk of sudden death in adolescents and young adults? *J Am Coll Cardiol.* 2003; 42(11):1959-63. <https://doi.org/10.1016/j.jacc.2003.03.002>.
19. Patel V, Elliott P. Sudden death in athletes. *Clin Med.* 2012;12(3):253-6. <https://doi.org/10.7861/clinmedicine.12-3-253>.
20. Marijon E, Tafflet M, Celermajer DS, Dumas F, Perier MC, Mustafic H, et al. Sports-related sudden death in the general population. *Circulation.* 2011;124:672-81. <https://doi.org/10.1161/CIRCULATIONAHA.110.008979>.

21. Chugh SS, Weiss JB. Sudden cardiac death in the older athlete. *J Am Coll Cardiol.* 2015;65(5):493-502. <https://doi.org/10.1016/j.jacc.2014.10.064>.
22. Krasi G, Precone V, Paolacci S, Stuppia L, Nodari S, Romeo F, et al. Genetics and pharmacogenetics in the diagnosis and therapy of cardiovascular diseases. *Acta Biomed.* 2019;90(10-S):7-19. <https://doi.org/10.23750/abm.v90i10-S.8748>.
23. Calkins H. Arrhythmogenic right-ventricular dysplasia/cardiomyopathy. *Curr Opin Cardiol.* 2006;21(1):55-63. <https://doi.org/10.1097/01.hco.0000198984.70884.4d>.
24. Corrado D, Pelliccia A, Bjørnstad HH, Vanhees L, Biffi A, Borjesson M, et al. Cardiovascular pre-participation screening of young competitive athletes for prevention of sudden death: proposal for a common European protocol. Consensus statement of the Study Group of Sport Cardiology of the Working Group of Cardiac Rehabilitation and Exercise Physiology and the Working Group of Myocardial and Pericardial Diseases of the European Society of Cardiology. *Eur Heart J.* 2005;26(5):516-24. <https://doi.org/10.1093/eurheartj/ehi108>.
25. Goh FQ, Kong WKF, Wong RCC, Chong YF, Chew NWS, Yeo TC, et al. Cognitive impairment in heart failure – a review. *Biology (Basel).* 2022;11(2):179. <https://doi.org/10.3390/biology11020179>.
26. Skalik R, Woźniak W, Borodulin-Nadzieja L. The efficiency of carbon dioxide output and ventilatory response while cardiopulmonary exercise test is related to cognitive performance irrespective of left ventricular contractile function. *Eur J Heart Fail Supplements.* 2010;9(S169):951.
27. Skalik R. Psychomotor performance is relevant determinant of cardiopulmonary capacity, *Eur J Heart Fail.* 2022; 24(Suppl S2):270. <https://doi.org/10.1002/ejhf.2569>.
28. Dridi H, Liu Y, Reiken S, Liu X, Argyrousi EK, Yuan Oi, et al. Heart failure-induced cognitive dysfunction is mediated by intracellular Ca²⁺ leak through ryanodine receptor type 2. *Nat Neurosci.* 2023;26(8):1365-78. <https://doi.org/10.1038/s41593-023-01377-6>.
29. Holm H, Bachus E, Jujic A, Nilsson ED, Wadström B, Molvin J, et al. Cognitive test results are associated with mortality and rehospitalization in heart failure: Swedish prospective cohort study. *ESC Heart Fail.* 2020;7(5):2948-55. <https://doi.org/10.1002/ehf2.12909>.
30. Janocha A, Bolanowski M, Pilecki W, Małyszczak K, Salomon E, Woźniak W, et al. Cognitive disorders in type 2 diabetic patients with recognized depression. *Neuroendocrinol Lett.* 2010;31(3):399-405.
31. Anguita M, Montes P, Jordán A, Casares G, Gómez I, Recio J, et al. Utility of NT-proBNP for diagnosing heart failure in a heterogeneous population of patients with dyspnea. Spanish Multicenter Study. *Rev Esp Cardiol.* 2006;59(5):465-72. [https://doi.org/10.1016/S1885-5857\(06\)60795-0](https://doi.org/10.1016/S1885-5857(06)60795-0).
32. Tromp J, van der Meer P, Tay WT, Ling LH, Loh SY, Soon D, et al. Diagnostic accuracy of the electrocardiogram for heart failure with reduced or preserved ejection fraction. *J Card Fail.* 2023;29(7):1104-06. <https://doi.org/10.1016/j.cardfail.2023.03.014>.
33. Davenport C, Cheng EYL, Kwok YTT, Lai AHO, Wakabayashi T, Hyde C. Assessing the diagnostic test accuracy of natriuretic peptides and ECG in the diagnosis of left ventricular systolic dysfunction: a systematic review and meta-analysis. *Br J Gen Pract.* 2006;56(522):48-56.
34. Skalik R. Screening of athletes: An electrocardiogram is not enough. *Herz.* 2015;40(3):386-94. <https://doi.org/10.1007/s00059-015-4214-6>.
35. Sylvia MT, Soundharia R, Bhat RV, Marak F. Myocardial bridging in cases of sudden death and its association with clinicopathologic characteristics. *Heart Views.* 2023;24(1):6-10. https://doi.org/10.4103/heartviews.heartviews_79_22.
36. Skalik R, Janocha A. Big atrial septal defect in asymptomatic athlete with persistent atrial fibrillation – relevance of cardiac magnetic resonance imaging for diagnostic proces. *Eur Heart J Cardiovasc Imaging.* 2017;18(Suppl_1):i56. <https://doi.org/10.1093/ehjci/jex081>.
37. Skalik R. Drowsiness as a first symptom of relevant atrial septal defect in young female athlete candidate. *Eur Heart J Cardiovasc Imaging.* 2017;20(Suppl_1):i1011. <https://doi.org/10.1093/ehjci/jey269>.
38. Steriotis AK, Nava A, Rigato I, Mazzotti E, Daliento L, Thiene G, et al. Noninvasive cardiac screening in young athletes with ventricular arrhythmias. *Am J Cardiol.* 2013; 111(4):557-62. <https://doi.org/10.1016/j.amjcard.2012.10.044>.
39. van de Sande DA, Hoogeveen A, Hoogsteen J, Kemps HM. The diagnostic accuracy of exercise electrocardiography in asymptomatic recreational and competitive athletes. *Scand J Med Sci Sports.* 2016;26(2):214-20. <https://doi.org/10.1111/sms.12420>.
40. Rizzo M, Spataro A, Cecchetelli C, Quaranta F, Livrieri S, Sperandii F, et al. Structural cardiac disease diagnosed by echocardiography in asymptomatic young male soccer players: implications for pre-participation screening. *Br J Sports Med.* 2012;46(5):371-3. <https://doi.org/10.1136/bjsm.2011.085696>.
41. Harris KM, Sponsel A, Hutter AM Jr, Maron BJ. Brief communication: cardiovascular screening practices of major North American professional sports teams. *Ann Intern Med.* 2006;145(7):507-11. <https://doi.org/10.7326/0003-4819-145-7-200610030-00008>.

42. Skalik R, Janocha A, Borodulin-Nadzieja L, Goździk A, Poręba R, Biały D, et al. The effect of different exercise protocols on leptin levels and regional left ventricular diastolic heart function among professional swimmers – a comparison with untrained subjects: a Doppler tissue imaging study. *Med Sport (Krakow)*. 2006;10(1):24-9.
43. Bystryk L, Nowosad H, Skalik R. Successful PTCA of right coronary artery stenosis in a patient with common origin of all three coronary arteries from a single ostium in the right sinus of Valsalva – a case report. *Kardiol Pol*. 2000;52(6):479-81.
44. Liu JE, Barac A, Thavendiranathan P, Scherrer-Crosbie M. Strain imaging in cardio-oncology. *JACC CardioOncol*. 2020;2(5):677-89. <https://doi.org/10.1016/j.jaccao.2020.10.011>.
45. Daniels CJ, Saurabh Rajpal S, Greenshields JT, Rosenthal GL, Chung EH, Terrin M, et al. Prevalence of clinical and subclinical myocarditis in competitive athletes with recent SARS-CoV-2 infection: Results from the big ten COVID-19 cardiac registry. *JAMA Cardiol*. 2021; 6(9):1078-87. <https://doi.org/10.1001/jamacardio.2021.2065>.
46. Escher F, Westermann D, Gaub R, Pronk J, Bock T, Al-Saadi N, et al. Development of diastolic heart failure in a 6-year follow-up study in patients after acute myocarditis. *Heart*. 2011;97(9):709-14. <https://doi.org/10.1136/hrt.2010.199489>.
47. Biały D, Derkacz A, Nowosad H, Skalik R, Marszałek E, Poręba R, et al. Electrocardiography and echocardiography in athletic heart imaging, *Biol Sport*. 2003;20(3): 195-208.
48. Nowosad H, Derkacz A, Skalik R, Poręba R, Węglowski J, Biały D. Nadciśnienie tętnicze a choroba wieńcowa. Jak często w badanej angiograficznie populacji nadciśnienie jest jedynym izolowanym czynnikiem ryzyka choroby wieńcowej?, *Adv Clin Exp Med*. 2002;11(3):307-12.
49. Kałka D, Domagała Z, Kołęda P, Marciniak W, Wojcieszczyk L, Janocha A, et al. Retrospective analysis of physical recreation intensity accomplished in primary and secondary prevention in invasively-treated patients with ischemic heart disease. *Adv Clin Exp Med*. 2011;20(3):313-24.