








CASUISTIC PAPER

Berrin Erok ¹, Kemal Harmancı ¹, Ferdi Aksaray ², Nazmi Uğur Unlu ³,
Seckin Aydın ³

A long clinical course with late distant metastases from follicular thyroid carcinoma

¹ Department of Radiology, University of Health Sciences, Prof. Dr. Cemil Tascioglu City Hospital, Istanbul, Turkey

² Department of Radiation Oncology, University of Health Sciences, Prof. Dr. Cemil Tascioglu City Hospital, Istanbul, Turkey

³ Department of Neurosurgery, University of Health Sciences, Prof. Dr. Cemil Tascioglu City Hospital, Istanbul, Turkey

ABSTRACT

Introduction. Follicular thyroid carcinoma (FTC) accounts for 10-20% of the differentiated thyroid carcinomas (DTCs), and it is the second most common thyroid malignancy after papillary thyroid carcinoma (PTC). FTC is typically more common in women and in older age group than PTC. Unlike PTC, FTC metastases late to the lymph nodes, with only up to 10-20% of the patients having nodal metastases at the time of diagnosis. On the other hand, distant metastasis via hematogenous spread is more likely in patients with FTC due to the invasion of blood vessels. Prognosis depends on the extent of the distant metastasis which drop 10-year survival significantly.

Aim. Although DTCs have usually favorable prognosis, metastatic disease in these patients has a long clinical course. Cranial imaging in these patients should be performed during the follow-up after the treatment of FTC with thyroidectomy and RAI.

Description of the case. We report a case of late onset but catastrophic hematogenous distant metastases beginning 8 years after the diagnosis & treatment of FTC and becoming widespread during the following 10 years with a long clinical course in a 60 year old female patient.

Conclusion. In the RAI refractory metastatic lesions SRS and surgical resections should be considered as the first management approach to improve survival.

Keywords. follicular thyroid carcinoma, brain metastasis, skull metastasis

Introduction

Follicular thyroid carcinoma (FTC) accounts for 10-20% of the differentiated thyroid carcinomas (DTCs), with higher prevalence in iodine deficient areas.^{1,2} It is the second most common thyroid malignancy after papillary thyroid carcinoma (PTC). FTC is typically more common in women and in older age group than PTC, presenting at about 40-60 years of age.³ It is the neoplasm of differentiated follicular cells, just like the follicular adenoma (FA). It is differentiated from FA by the presence

of capsular and/or vascular invasion and from the PTC by the absence of characteristic nuclear features.⁴ Surgical resection is needed for accurate diagnosis. Unlike PTC, FTC metastases late to the lymph nodes, with only up to 10-20% of the patients having nodal metastases at the time of diagnosis. On the other hand, distant metastasis via hematogenous spread is more likely in patients with FTC due to the invasion of blood vessels.⁵ Prognosis depends on the extent of the distant metastasis which drop 10-year survival significantly.

Corresponding author: Berrin Erok, e-mail: drberrinerok@hotmail.com

Received: 27.06.2021 / Revised: 17.07.2021 / Accepted: 19.07.2021 / Published: 30.12.2021

Erok B, Harmancı K, Aksaray F, Unlu NU, Aydın S. *A long clinical course with late distant metastases from follicular thyroid carcinoma.* Eur J Clin Exp Med. 2021;19(4):347–351. doi: 10.15584/ejcem.2021.4.11



Aim

We report a case of late onset but catastrophic haemogenous distant metastases beginning 8 years after the diagnosis & treatment of FTC and becoming widespread during the following 10 years with a long clinical course in a 60 year old female patient.

Description of the case

In 2003, when the patient was 42-year old, she was diagnosed with FTC and treated with total thyroidectomy and radioiodine (RAI). In 2011 (8 years after the treatment of FTC), her serum thyroglobulin (Tg) level started to be increased and the first distant metastasis was established on the left femur. She was treated with total hip arthroplasty and started to be followed up more closely. In 2012, she came to our hospital and examinations revealed multiple lung (Fig. 1) and right clavicle metastases (Fig. 2).

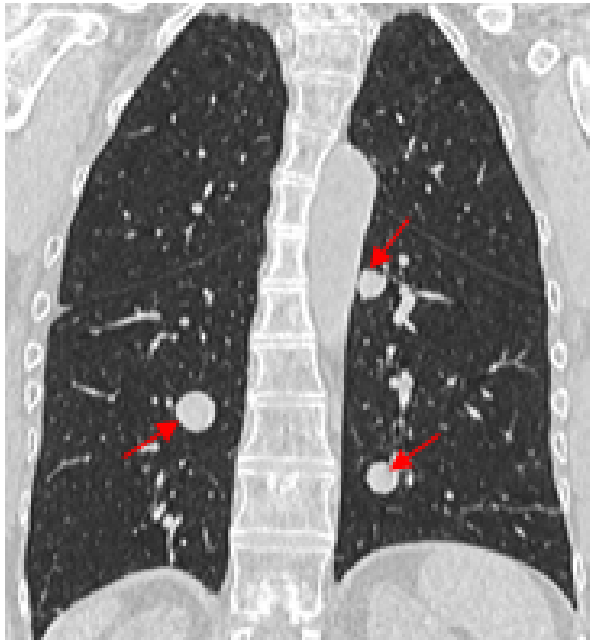


Fig. 1. Coronal pulmonary CT image showing multiple well defined lung metastasis from FTC (arrows)

She was admitted for treatment with RAI and radiotherapy. However, since she became refractory to RAI, Lu-177 treatment was applied. She was also under the treatment of a tyrosine kinase inhibitor (TKI) at that time. In 2014, she presented with a left frontoparietal skull metastasis. Brain magnetic resonance imaging (MRI) revealed a 55x35x25 mm sized metastatic lesion involving the epidural space and adjacent dura, characterized with heterogenous signal intensity on T2w images and hemorrhagic components on T1w and gradient echo (GRE) images. Prominent contrast enhancement was present after gadolinium (Fig. 3).

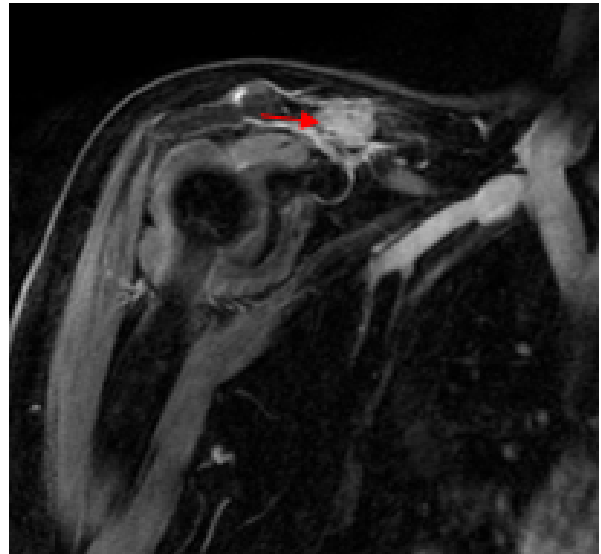


Fig. 2. Coronal postcontrast T1w shoulder MRI showing obviously enhancing metastatic lesion of the right clavicle (arrow)

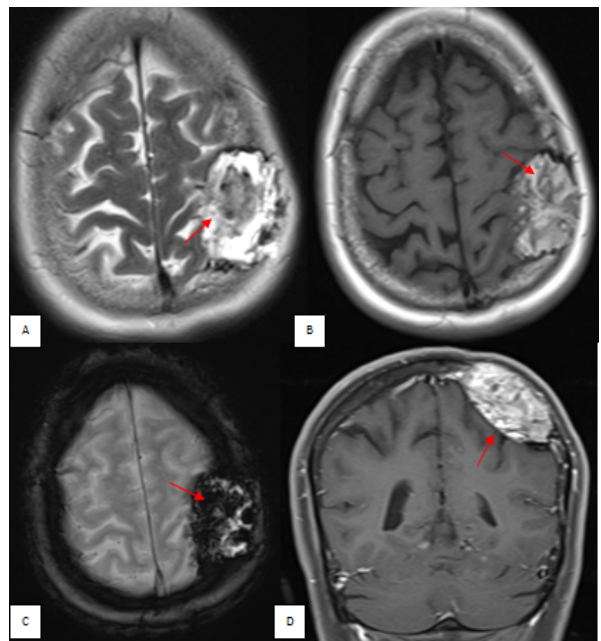


Fig. 3. MRI of the brain showing a 55x35x25 mm sized left frontoparietal skull metastasis having heterogenously high signal intensity on axial T2w (A, arrow), spontaneous hemorrhagic hyperintensities shown on T1w (B, arrow) and signal void areas corresponding to the hemorrhagic components on GRE images (C, arrow). Prominent enhancement of the mass is demonstrated on coronal postcontrast T1w image (D, arrow). Note the epidural extension of the lesion with compression of the neural parenchyma without invasion

At that time, due to the development of myelodysplastic syndrome, surgical removal of the metastatic lesions had to be started. Between the years 2017–2021, right clavicle, left frontoparietal and left mandibular

bone metastases was surgically treated. After 1 year another skull metastasis appeared at the posterior parietal region invading the superior sagittal sinus and then another at the left parietal bone. Both were also surgically removed (Fig 4).

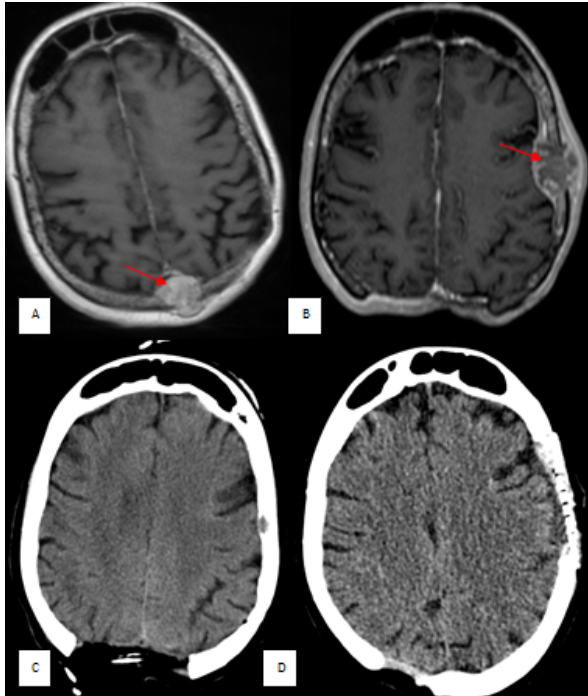


Fig. 4. (A, B) Axial postcontrast T1w MRI of the brain showing 2 cm sized midline posterior parietal bone metastasis invading the superior sagittal sinus (A, arrow) and 35x25 mm sized left parietal bone metastasis (B, arrow) involving to the adjacent scalp and dura with epidural extension. Surgical removal of both lesions is seen on axial CT images (C, D)

Then the disease progressed rapidly with newly appeared multiple skull metastases in addition to the first cerebral metastasis in the right occipital lobe (Fig. 5). Since the radioiodine scan was negative, GA-63 DO-TA-TATE PET-CT was performed to demonstrate all the metastatic lesions (Fig. 6)

Discussion

In DTCs the most common sites of distant metastasis are lung and extracranial bones.⁶ Skull bones are rare sites and when occurred there are usually lung and other extracranial bone metastases. Metastatic tumors to the skull are most often from lung, breast, and prostate malignancies.⁷ Involvement of the dura and scalp may occur in these cases, as in our patient. In a study including 473 patients with all types of thyroid cancers conducted by Negamine et al. skull metastasis was established only in 12 (2.5%) of the cases.³ The average period from diagnosis of the thyroid cancer until the appearance of the skull metastasis was 23.3 years. In our

patient the first distant metastases occurred 8 years after the treatment of FTC. The appearance of the first skull metastasis occurred 11 years and the brain metastasis occurred 18 years after the diagnosis. Brain metastasis from DTCs is much more rare with reported prevalence between 0.15% to 1.4% of the cases in different studies.⁸

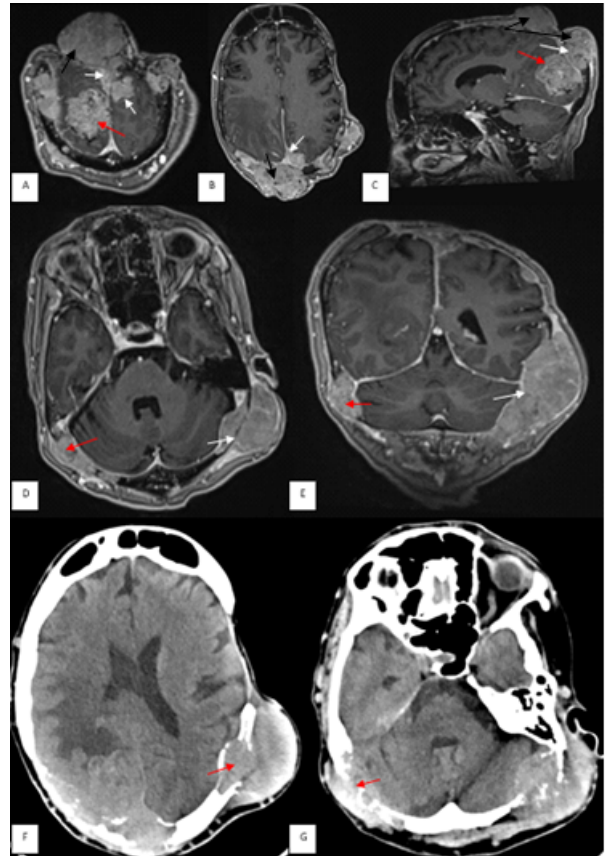


Fig. 5. (A-E) The last follow-up MR images demonstrating multiple obviously enhancing skull bone and cerebral metastases. Coronal (A), axial (B) and sagittal (C) postcontrast MR images showing the right occipital parenchymal metastasis which is 4 cm in diameter (A, C; red arrows). Multiple extraaxial dural based metastasis are shown (A, B, C; white arrows). 51x37 mm and 55x34 mm sized posterior parietal (A, B, C; black arrows), 45x20 mm sized right occipital (D, E; red arrows) and 95x50 mm sized left occipital (D, E; white arrows) metastases invading the transverse sinuses are shown. F, G) Axial CT images showing lytic and expansile behaviour of the skull metastases (F, G; arrows)

Metastatic tumors to the brain are most often from lung cancer, breast carcinoma, renal cell carcinoma, melanoma and gastrointestinal tract adenocarcinomas.⁷ In the literature, regarding the histopathological subtypes, among the brain metastasis from DTCs, there is a predominance of PTC which is most probably due to its much more higher prevalence than FTC.⁹ Although, in most of the reported cases, the appearance of distant

metastasis occur long after the initial diagnosis as in our case, distant metastasis at the time of diagnosis of FTC may also occur in up to 20% of the cases.^{6,7} The metastatic masses of FTC are highly vascular lesions showing prominent contrast enhancement on imaging studies and having expansive-lytic appearance when involved to the bones. Prognosis in patients with distant metastasis is poor and its poorer in case of skull metastasis. In the study of Nagemina et al. mean survival in patients with skull metastasis was reported as only 4.5 years.³ The prognosis is even worse with reported mean survival time of 12.4 months when brain metastasis occurred from DTC in a study including 32 patients.¹⁰ When the radioiodine scans are negative, 18F-FDG PET/CT can be used for detection of recurrent and metastatic lesions in follow up of patients with increased Tg level. However, it may also not detect the tumor in all patients, as in our case. In such cases PET-CT imaging with Ga-68-labelled DOTA-somatostatin analogues is useful to demonstrate metastatic masses.¹¹ We used octreotate (Ga-68-DOTA-TATE) in our patient.

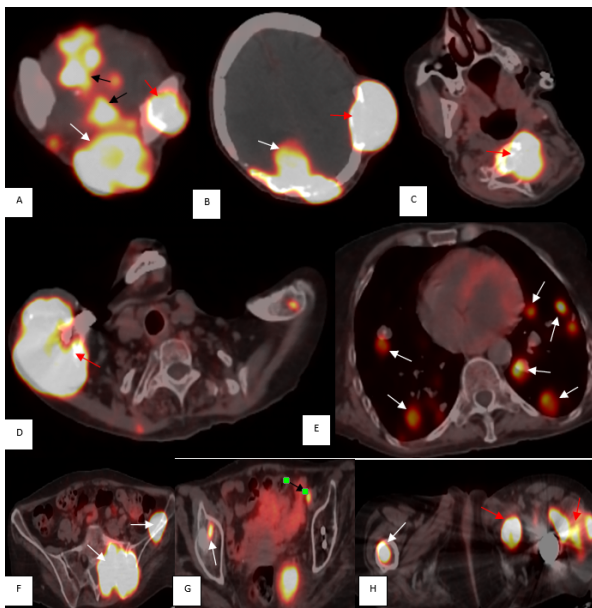


Fig. 6. Whole body DOTA-TATE PET-CT images showing right occipital cerebral metastasis (A, B; white arrow), multiple extraaxial dural based metastases invading the superior sagittal sinus (A, black arrows) and skull bone metastases (A, B; red arrows), metastatic masses involving the cervical vertebrae (C, arrow), the distal part of the right clavicle (D, arrow), multiple pulmonary nodular metastases (E, arrows), the right sacroiliac metastases (F, arrows), the right acetabular (G, white arrow) and the right femoral head (H, white arrow) metastases and the multiple metastatic masses involving the muscle groups of the left femoral region (H, red arrows). Note the small external iliac lymph node metastasis (G, black arrow)

In the treatment of metastatic disease, iodine concentrating tumors can still be treated with RAI, however when the recurrent or metastatic masses from DTC lose their ability to concentrate RAI they poorly respond with a low remission rate.¹² In the 2015 American Thyroid Association guidelines for the brain metastases from DTC surgical resection and stereotactic radiosurgery (SRS) are recommended as the mainstay of therapy.¹³ In one study the median survival time in patients treated with surgery and/or SRS was reported as 11.9 months in contrast to the median survival time of 7.1 months in patients who were not treated with surgery and/or SRS.⁸ The median survival time of 19 months was reported in patients with RAI-refractory DTC when TKIs were combined with local treatment.¹⁴ Number of surgical resections of extracranial and skull bone metastases were performed in addition to SRA in our patient in addition to the treatment with a TKI.

Conclusion

Although DTCs have usually favorable prognosis, distant hematogenous metastasis is an important concern after the treatment of FTC with thyroidectomy and RAI. Cranial imaging in these patients should be performed during the follow-up. The metastatic disease in these patients has a long clinical course and should be managed appropriately. In the RAI refractory metastatic lesions SRS and surgical resections should be considered as the first management approach to improve survival.

Declarations

Funding

This research received no external funding.

Author contributions

Conceptualization, B.E.; Methodology, B.E. and K.H.; Validation, B.E., K.H. and F.A.; Formal Analysis, B.E. and K.H.; Investigation, B.E.; Data Curation, B.E. and S.A.; Writing – Original Draft Preparation, B.E.; Writing – Review & Editing, B.E., F.A., N.U.U., and S.A.; Supervision, B.E., F.A. and N.U.U.

Conflicts of interest

The authors declare no conflict of interest.

Data availability

All data generated or analyzed during this study are included in this article [and/or] its supplementary material files. Further enquiries can be directed to the corresponding author.

Ethics approval

Informed consent was taken from the patients.

References

1. Ito Y, Hirokawa M, Masuoka H, et al. Distant metastasis at diagnosis and large tumor size are significant prognostic factors of widely invasive follicular thyroid carcinoma. *Endocr J*. 2013;60:829-833.
2. De Crea C, Raffaelli M, Sessa L, et al. Actual incidence and clinical behaviour of follicular thyroid carcinoma: an institutional experience. *ScientificWorldJournal*. 2014;2014:952095.
3. Nagamine Y, Suzuki J, Katakura R, Yoshimoto T, Matoba N, Takaya K. Skull metastasis of thyroid carcinoma. Study of 12 cases. *J Neurosurg*. 1985;63:526-531.
4. DeLellis RA, Lloyd RV, Heitz PU, et al. World Health Organization classification of tumors: pathology and genetics of tumors of endocrine organs. Lyon: IARC Press; 2004; 64-66.
5. Kim HJ, Sung JY, Oh YL, Kim JH, Son YI, Min YK, et al. Association of vascular invasion with increased mortality in patients with minimally invasive follicular thyroid carcinoma but not widely invasive follicular thyroid carcinoma. *Head Neck*. 2014;36:1695-1700.
6. Schlumberger M, Tubiana M, De Vathaire F, et al. Long-term results of treatment of 283 patients with lung and bone metastases from differentiated thyroid carcinoma. *J Clin Endocrinol Metab*. 1986;63:960-967.
7. Kumar V, Abbas AK, Fausto N, et al. Robbins and Cotran pathologic basis of disease. *W B Saunders Co*. 2005;2005:0721601871.
8. de Figueiredo BH, Godbert Y, Soubeyran I, et al. Brain metastases from thyroid carcinoma: a retrospective study of 21 patients. *Thyroid*. 2014;24(2):270-276.
9. Choi J, Kim JW, Keum YS, Lee IJ. The largest known survival analysis of patients with brain metastasis from thyroid cancer based on prognostic groups. *PLoS One*. 2016;11(4):e0154739
10. Chiu AC, Delpassand ES, Sherman SI. Prognosis and treatment of brain metastases in thyroid carcinoma. *J Clin Endocrinol Metab*. 1997;82(11):3637-3642.
11. Binse I, Poeppel TD, Ruhlmann M, et al. 68Ga-DOTA-TOC PET/CT in Patients with Iodine- and 18F-FDG-Negative Differentiated Thyroid Carcinoma and Elevated Serum Thyroglobulin. *J Nucl Med*. 2016;57(10):1512-1517.
12. Durante C, Haddy N, Baudin E, et al. Long-term outcome of 444 patients with distant metastases from papillary and follicular thyroid carcinoma: benefits and limits of radioiodine therapy. *J Clin Endocrinol Metab*. 2006;91:2892-2899.
13. Haugen BR, Alexander EK, Bible KC, et al. 2015 American Thyroid Association management guidelines for adult patients with thyroid nodules and differentiated thyroid cancer: The American Thyroid Association Guidelines Task Force on Thyroid Nodules and Differentiated Thyroid Cancer. *Thyroid*. 2016;26(1):131-133.
14. Gomes-Lima CJ, Wu D, Rao SN, et al. Brain Metastases From Differentiated Thyroid Carcinoma: Prevalence, Current Therapies, and Outcomes. *J Endocr Soc*. 2018;21;3(2):359-371.